HOW TO PERFORM A STANDARD TRANSTHORACIC ECHO

OPTIMIZING THE ECHO IMAGE

Adjusting the location and orientation of the probe:

1. Sliding the transducer in all directions (vertical/horizontal, medial/lateral or oblique directions)
2. Rotating the transducer (clockwise or anticlockwise). **Hint:** The transducer groove (or dot) should point toward the right shoulder in the PLAX and A3C, and toward the left shoulder in the PSAX and A2C.
3. Tilting the plane (medial/lateral or anterior/posterior)

Adjusting the patient's location and breathing (of utmost importance):

1. Repositioning the patient slowly more laterally (or less)
2. Asking the patient to breath in slowly (or to take a small breath) and then to breath out slowly and hold when the figure is optimum

Adjusting the knobs:

1. Adjust the depth and Focus the beam at the primary depth of interest ± adjust the width
2. Adjust the overall gain (the active gain knob): auto-gain if available, first, then manually adjust.
3. Adjust the TGC, to make the near to far field appear evenly-lit.
4. Consider adjusting the grey scale compression (contrast) to control weak echoes.
5. Very rarely consider adjusting line density, power and fine tuning frequency of the transducer)
6. After adjusting the knobs you may consider readjusting the patient position and breathing whilst trying to optimize the image.

TRANSTHORACIC ECHO WINDOWS

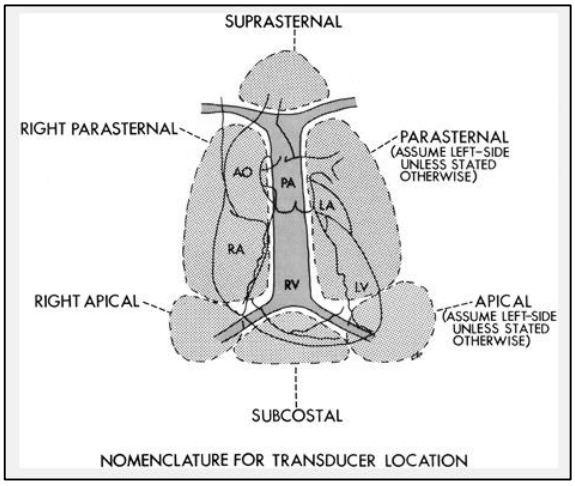

There are 4 standard transducer positions useful to scan the heart, called "acoustic windows" or "approaches": (1) parasternal and (2) apical approaches are obtained with the patient in left lateral decubitus position; (3) subcostal and (4) suprasternal with the patient in supine position. (5) the right parasternal view is obtained by rolling the patient on the right side. The most frequently used acoustic windows in adults are the parasternal and the apical. In paediatric patients and in adults with a limited acoustic window due to respiratory diseases the subcostal approach sometimes is the only one possible. Finally, the suprasternal approach is a complementary view to explore the aortic arch and supraaortic vessels, the first part of descending thoracic aorta and to measure aortic gradient in difficult patient. Occasionally, the right parasternal window can be used to image the ascending aorta and record transaortic gradients. In some pathological conditions (i.e. dextrocardia or pneumothorax) its necessary to use non-standard or "off axis" views. Usually the transducer position is at the apex of the image sector. Conventionally, in transthoracic echocardiography, 'superficial' or 'anterior' structures are displayed in the 'upper' part of the image, whereas 'deeper' or 'posterior' structures are located in the 'lower' part of the image sector. Lateral structures are displayed on the right side of the screen and medial structures on the left side

PLAX VIEW:

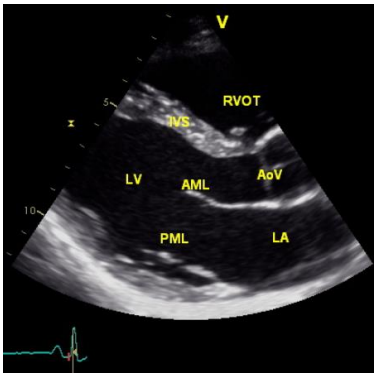

- Put the patient on left lateral position for better image quality.
- Place the transducer near the sternum in the third or fourth left intercostal space and point the transducer groove (or dot) toward the patient's right shoulder.
- Slide and rotate the transducer in all directions until the ultrasound beam is parallel to the long axis of the heart.
- Tilt the plane laterally/medially gradually until the left ventricular size is at its maximum and MV leaflet excursion is greatest. This is the point where the ultrasound beam passes through the centre of the LV at its major axis.
- Consider turning the patient slightly towards the supine position or more acute left lateral to optimize the image (if needed)
- **In this view you can see**:
  - RVOT is the closest structure to the transducer.
  - Anterior IVS (anteroseptal wall), LV cavity and the inferolateral wall are the structures below the RVOT on the left side of the image sector. The true LV apex is missed in this view. If you see LV apex in this view it usually means foreshortened LV.
  - Aortic root lies below the RVOT on the right side of the image sector. It is usually easy to see the sinuses of Valsalva, the sinotubular junction, and the proximal part of the ascending aorta.
  - Aortic Valve (**RCC & NCC**) in systole is usually visualized as two thin linear images parallel to the walls of the ascending thoracic aorta; the upper (anterior) aortic cusp corresponds to the right coronary cusp and the lower (posterior) one to the non-coronary cusp.
  - MV (usually **A2 & P2**) lies just below the aortic root (the most posterior valve in this view). The AML is in close continuity with the non-coronary AV cusp. Both AML & PML are attached by many tendinous chords (chordae tendineae) to papillary muscles (AML to AL muscle & PML to PM muscle)
  - LA is seen in the lower right region of the image sector.
  - Pericardium sometimes can be identified at the lower edge of the LA and LV. A narrow, echo-free space behind the posterior left ventricular wall, but anterior to the descending aorta is strongly suggestive of pericardial fluid.
  - Coronary sinus lies at the AV junction just below the base of the posterior mitral leaflet and moves with the AV groove during the cardiac cycle.
  - Descending thoracic aorta lies posterior to the LA and external to the pericardium. In comparison to the CS, it is larger, lies more posteriorly and is fixed (does not move during the cardiac cycle).

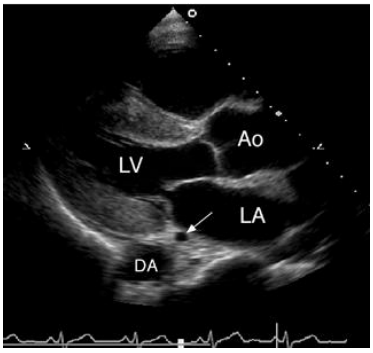

- **Use 2-D ± M-mode ± zoom to assess**:
  - LV walls motion (align cursor perpendicular to walls correctly): anteroseptal and inferolateral walls.
  - Structure and mobility of the aortic valve. The RCC & NCC are visible and normally have a central closure line – an eccentric closure line suggests bicuspid aortic valve
  - Structure and mobility of the mitral valve – in this view, the A2 and P2 segments are visible
  - Inspect the ascending aorta; do not forget to look at the descending aorta as it runs behind the left atrium – this is a useful landmark for assessing a pericardial/pleural effusion.
- **Apply color Doppler** window across the mitral and aortic valves to visualize any MR or AR if present. Consider applying zoom on either if needed. Slight medial angulation provides an excellent opportunity to detect flow through a ventricular septal defect.
- **Freeze the screen to measure**:
  - Proximal RVOTd (figure)
  - LA size at its widest dimension (end ventricular systole). Unfreeze once done.
  - LV size and dimensions (IVSd, LVIDd and LVPWd, and LVIDs). Line of measurements should perpendicular on the long axis of the LV at the level of the tips of the open MV leaflets (in either 2D or m-mode).

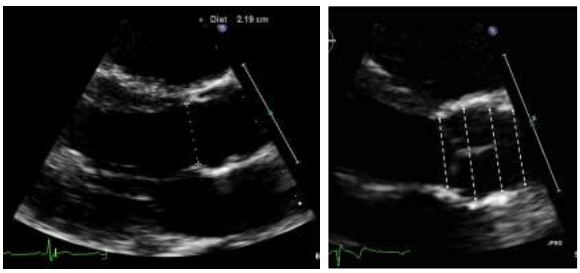

- **Zoom at the LVOT and Freeze** the screen to measure LVOT diameter at the base of the aortic cusps at peak of systole (aortic valve maximally open).
- **The true dimensions of the proximal aorta** are underestimated in the properly aligned parasternal long-axis. Slight counterclockwise rotation of the transducer and Tilting of the U/S beam laterally will open the aortic root and demonstrate the true long axis of the aorta. Measure the aortic root at level of annulus, **SoV**, STJ and proximal ascending aorta (inner edge to inner edge, at widest diameter).
- **Apply M-mode** cursor at the AV level then the MV level then the LV mid ventricular level. Consider taking measurements of the aortic root, LV & LA if 2D image is on axis.

PLAX RV INFLOW VIEW

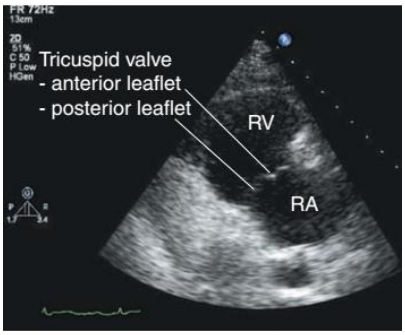

- Tilt the ultrasound beam slightly toward the right hip (inferiorly & medially) to visualize the RV inflow, RA and the tricuspid valve, (slight clockwise rotation of the transducer is generally required because the right ventricular inflow tract is not parallel to its left ventricular component). In this plane, the important landmark is the tricuspid valve and the plane is considered optimized when the full excursion of the anterior and posterior tricuspid leaflets is seen and the RV dimension is greatest. Posterior leaflet seen only in this view and possibly in the PSAX view. Other views (apical 4C & subcostal 4C) show anterior and septal leaflets.
- **Use 2-D ± M-mode ± zoom to assess**:
  - The structure and mobility of the tricuspid valve
  - The size and function of the RV.
  - The structure of the RA. In this view it may be possible to see the coronary sinus and the inferior and superior vena cavae as they join the RA.
  - There may be a prominent Eustachian valve at the junction with the inferior vena cava.
- **Use colour Doppler** to examine tricuspid valve inflow and check for regurgitation.
- **Use continuous wave (CW) and pulsed wave (PW)** Doppler to assess tricuspid valve function. If tricuspid regurgitation is present, measure the maximum velocity to assess RV systolic pressure.

PLAX RVOT VIEW

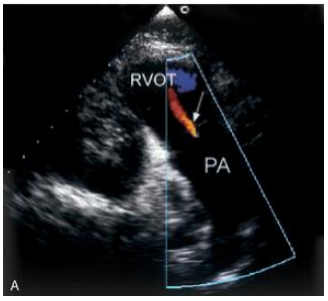

- Tilt the ultrasound beam slightly towards the left shoulder to visualize the RVOT and PA (including PA bifurcation).
- **Apply color Doppler** to visualize any TR if present. You can record pulmonary valve inflow by **PW** (1cm proximal to the pulmonary valve) and measure the PR jet velocity by placing the **CW** cursor within the jet. To record the bifurcation of the main pulmonary artery, either this view or the basal short-axis view is ideal.

PSAX BASAL LEVEL

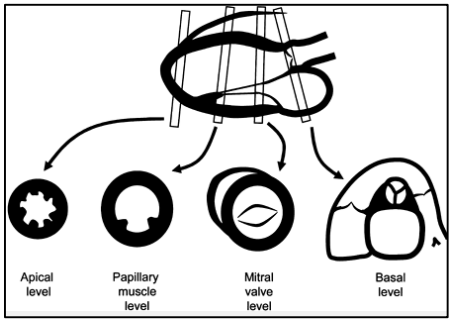

- From the parasternal long-axis transducer position, rotate the transducer clockwise approximately 90 degrees to moves the imaging plane to the short-axis view. The transducer groove (or dot) should point toward left shoulder now.
- The relationship of the various short-axis planes to the long-axis view is demonstrated in the figure and can be used as a guide to optimize the target structure in the PLAX view then rotating the transducer to move the image plan to the PSAX view.
- A useful reference point to begin the short-axis examination is the tip of the anterior mitral valve leaflet. Slide and rotate the transducer slightly and tilt the plane until the left ventricle appears circular and both leaflets of the mitral valve demonstrate maximal excursion (usually the transducer is pointed directly posteriorly). In this plane both mitral leaflets can be seen clearly. The PML looks smaller and is located from 3 to 8 O'clock inferiorly. AML looks larger and occupies the rest of the circle anteriorly. Minor base-to-apex angulation is useful to record the orifice of the mitral valve, the coaptation of the leaflets, and the mitral chordae and their insertion into the anterior and posterior papillary muscles.

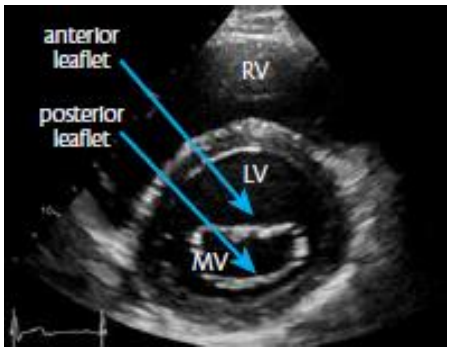

- Mitral flow is nearly perpendicular to the scan plane, therefore quantitative Doppler assessment of mitral flow is not possible. However, colour flow imaging (± zoom) may allow visualization of the mitral regurgitant jet. Scanning carefully through the plane of the mitral leaflets, the location and extent of the regurgitant orifice can often be identified.
- This plane allows also recording of basal left ventricular wall motion, and visualization of a portion of the right ventricle.
- The normal IVS curvature can be appreciated and any abnormalities of septal position, shape, or motion can be assessed. Sweep beam from base to apex to check the integrity of ventricular septum and exclude VSD.

PSAX MID & APICAL LEVELS

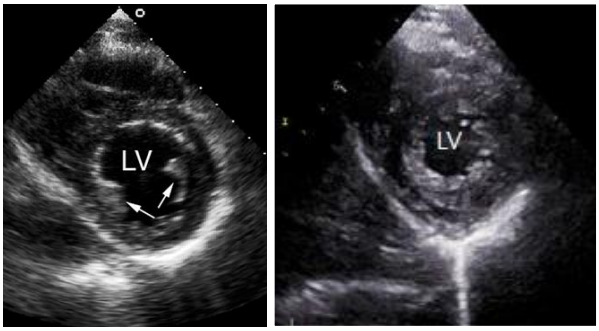

- Tilt the scan plane more caudally towards the apex, to sweep the image through the papillary muscle level (anterolateral at 3-4 O'clock & posteromedial at 8 O'clock) and then the left ventricular apex. Because these different planes span several centimetres, you may need to move the transducer to a lower interspace ± tilting at various angles. This series of views is ideal for assessing the contractile pattern of the left ventricle at the midventricular and apical levels. When recording these views, adjustments are aimed at maintaining the near-circular appearance of the left ventricular cavity.

PSAX AV LEVEL

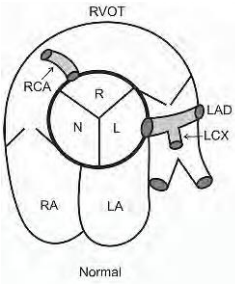

Tilt the scan plane more cranially towards the base of the heart ± move the transducer to a higher interspace so that the short-axis view approaches the level of the aortic annulus and allows simultaneous visualization of several important structures: the aortic annulus, the AV, coronary ostia, LA, IAS, RA, tricuspid valve (anterior and septal leaflets), RVOT, pulmonary valve, and proximal pulmonary artery. Occasionally, the LAA also can be visualized from this plane.

- The aortic valve has three cusps of equal size, which open widely during systole and close in a Y-shaped appearance in diastole.
- Each cusp is surrounded by (and named after) an outpouching in the aortic root called "sinus". The sinuses support the cusps during systole and provide a reservoir of blood to augment coronary flow during diastole.
- The right and left sinuses give rise to the right and left main coronary arteries respectively (can be seen in the PSAX at 4 O'clock & 11 O'clock respectively) and the third sinus is conveniently termed the non-coronary aortic sinus.

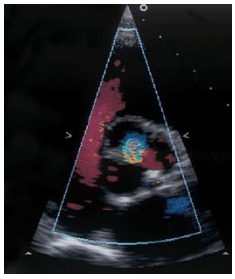

- In PSAX, the right coronary cusp is anterior, closest to the RV and the left coronary cusp is posterior and leftward, closest to the PA. The third, or noncoronary cusp, is posterior and rightward, just above the base of the IAS.
- The AV supports its own structure and does not have papillary muscles.
- Apply colour Doppler to check for **AR- aortic flow** is nearly perpendicular to the scan plane, therefore quantitative Doppler assessment of aortic flow is not possible. However, colour flow imaging just below the aortic valve (at the level of the LVOT) may allow visualization of the AR jet as it emerges from the regurgitant orifice. An assessment of regurgitant jet area at this level is useful.

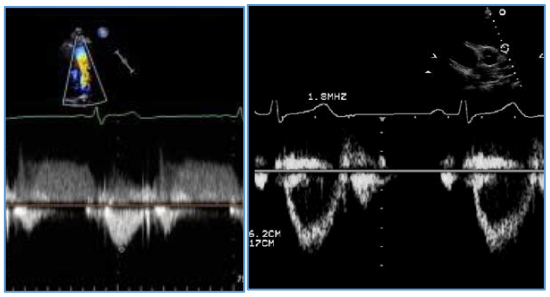

- Apply colour Doppler and CW to check for **TR**- At this view, blood flow is oriented nearly parallel to the ultrasound beam through both the tricuspid and pulmonary valves. Both **tricuspid inflow** and tricuspid regurgitation can be recorded from this position using colour mode & CW Doppler.
- Apply colour, PW and CW to assess the pulmonary flow and **PR-** asses pulmonary valve using colour Doppler and PW Doppler (1 cm proximal to the PV in the RVOT). Wait for few beats running until clear and sharp envelops seen. Freeze and move the trackball forward/backward to choose & record the best optimized images. PR can be recorded using CW Doppler.

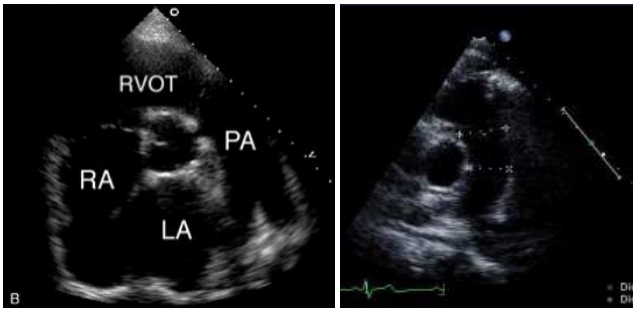

- You may check for ASD in this view by colour Doppler
- Follow the pulmonary artery to its bifurcation by sliding the transducer superiorly and laterally/medially &/or rotating the transducer anticlockwise/clockwise (likely anticlockwise) &/or tilting the plane slightly superiorly/laterally.
- You can measure the PV annulus and the main PA.

APICAL 4 CHAMBER

- Tilt the patient into a steep left lateral decubitus position and abducting the left arm.
- By palpation, locate the cardiac apex.
- To obtain the apical four-chamber view, place the transducer at the cardiac apex so that the transducer groove (or dot) points toward the patient's left axilla and the ultrasound beam points toward the patient's right scapula.
- Use the lowest intercostal space showing 4C to avoid LV foreshortening. The normal true apex is bullet-shaped and can be identified by its relatively thin walls and lack of motion. If the image is foreshortened (rounded instead of bullet-shaped LV apex), slide the transducer caudally &/or laterally.

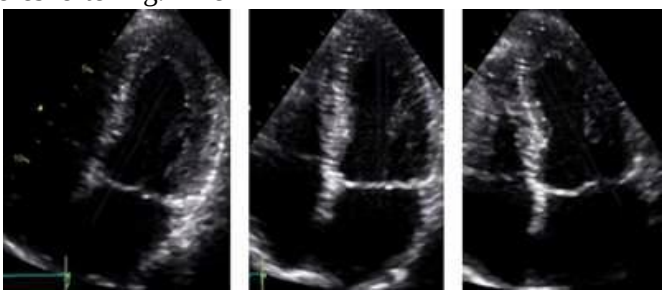

- Slide the transducer and rotate and tilt the plane until all four chambers of the heart are optimally visualized. You may need to reposition the patient &/or ask him to breath in then to breath out slowly and hold when the figure is optimum.This occurs when the full excursion of both mitral and tricuspid valves is recorded and the true apex of the left ventricle lies in the near field. A standard apical window gives an upright image (Fig. centre) compared with a too-medial window (Fig. left) and a too-lateral window (Fig. right).
- If you see the aortic valve at the junction between the 4 chambers (5C view), tilt the plane more posteriorly to remove the aortic valve from the view.
- Adjust the depth ± the width so that all 4 chambers are fully visualized and occupy the whole screen
- The AML is seen medially (near the anteriorly located RV) and the smaller PML is seen as it arises from the lateral margin of the atrioventricular ring. The septal leaflet of the tricuspid valve inserts medially and the larger anterior leaflet arises laterally. The insertion of the septal leaflet of the tricuspid valve is several millimetres more apical than the insertion of the mitral leaflet.

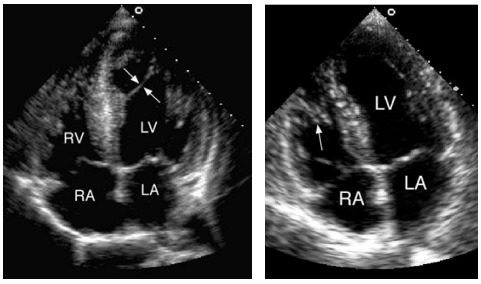

- The junction of the pulmonary veins into the posterior wall of the LA often can be seen.
- The descending aorta can frequently be visualized behind the left atrium
- Posterior tilt can reveal the coronary sinus
- The moderator band is often seen in the RV apex (figure).
- A common variant seen in normal hearts is the false tendon in the LV apex (figure).
- Assess contractility of LV segments (you may consider reducing the depth to concentrate on the LV):
  - Basal and mid anterolateral → apical lateral
  - Basal and mid inferoseptal → apical septal (posterior part of IVS is seen in apical 4C and more anterior part is seen in apical 5C)
  - Apex

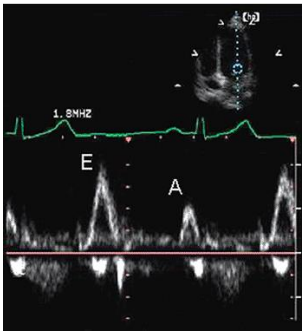

- Measure the LV area/volume, LA volume and TAPSE (± MAPSE)
- Apply color Doppler window on the mitral valve to check for MR. The color Doppler should overlay all of the LA. The pulmonary vein(s) can be seen in the majority of cases.
- With color Doppler on, place the cursor parallel to the mitral inflow (red flow), place the pulse-wave Doppler sample volume (small circle or line seen on the cursor) between the tips of mitral leaflets (on the LV side). Wait for few beats running until clear and sharp envelops seen. Freeze and move the trackball forward/backward to choose & record the best optimized images.

- In case of suspected tamponade or constrictive pericarditis, the PW Doppler recording of mitral **and tricuspid** inflow velocities should be performed at both a slow and a fast sweep speed. The slow speed is useful for evaluation of respiratory variation, whereas the fast speed is used to obtain measurements
- MR can be recorded using CW Doppler.
- Locate the right upper pulmonary vein flow (red flow near the interatrial septum), place the sample volume of PW Doppler 2 mm inside the vein to record the forwards flow waves (S, systolic wave and D, diastolic wave) and backward flow wave (A, reversed or negative flow wave occurring just before QRS in sinus rhythm).
- Tissue Doppler of mitral annulus can be done to complement the diastolic function assessment.
- An analogous approach can be taken to sample tricuspid inflow.

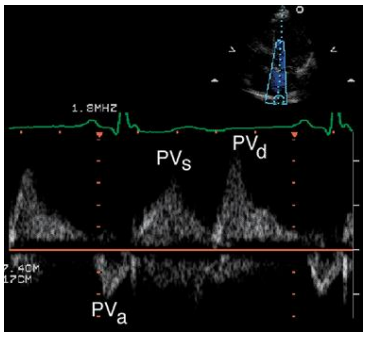

APICAL 5 CHAMBER

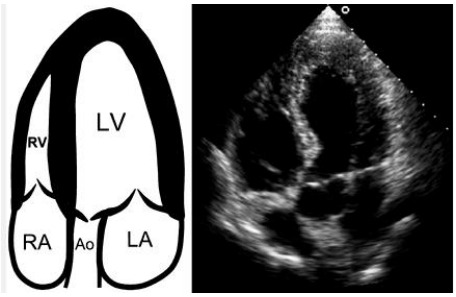

- Tilt the transducer anteriorly into a shallower angle relative to the chest wall so that LVOT**,** AV**,** and aortic root can be recorded. Anterior part of IVS is seen in apical 5C and more posterior part is seen in apical 4C. LV cavity may be distorted in this view. The view has several practical uses. It places both the left ventricular inflow and left ventricular outflow roughly parallel to the ultrasound beam. LVOT diameter may be measured from 5CV or 3CV at similar level as LVOT PW Doppler velocity trace obtained, typically 0.5-1.0 cm below AV annulus in calcific AS, and just at AV annulus level in bicuspid AS.
- Apply color Doppler window over the LVOT and AV, check for AR.
- To measure V_{LVOT} (V1), place PW sample volume in the LVOT just before AV (0.5-1.0 cm from AV annulus in calcific AS, and just at AV annulus level in bicuspid AS). Wait for few beats running until clear and sharp envelops seen. Freeze and move the trackball forward/backward to choose & record the best optimized images. Measure the R-R interval for cardiac output calculation.
- Switch to CW to obtain the AV velocity (V2) envelope. Wait for few beats running until clear and sharp envelops seen. Freeze and move the trackball forward/backward to choose & record the highest velocity.

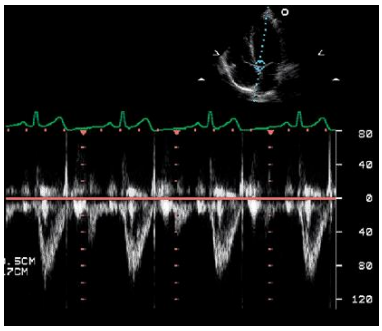

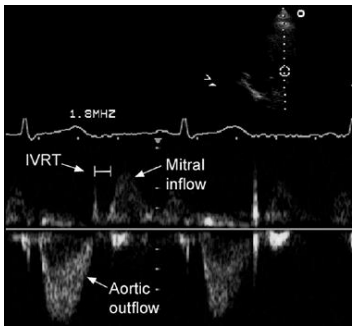

APICAL 2 CHAMBER

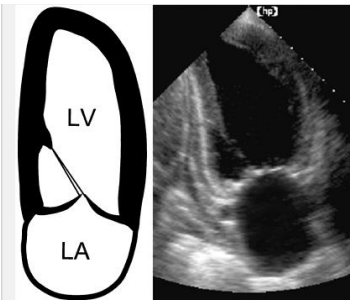

- Rotate the transducer anticlockwise approximately 60 degrees or more (until the RV and RA disappear and the liver tissue being there instead. Before you rotate make sure that the centre line of the image passes through the centre of the left ventricle and the left atrium is displayed in its full length. When rotating the transducer you should not alter your angulation or lose your position. The transducer groove (or dot) should point toward left shoulder now. You may need to reposition the patient &/or ask him to breath in then to breath out slowly and hold when the figure is optimum. The intent here is to completely exclude the right atrium and ventricle from the recording so that only the left ventricle, left atrium, and mitral valve are visualized.

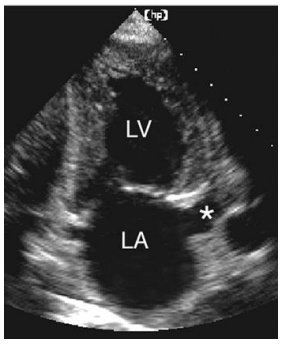

- The two-chamber view is similar in orientation to the right anterior oblique (RAO) angiographic view. Although not truly orthogonal to the four-chamber view, the apical two-chamber image records different walls of the left ventricle (Inferior wall is on the left side of the screen and anterior wall is on the right) and the combination of these two views (4C & 2C) often provides an accurate representation of left ventricular size, shape, and function. 4C & 2C are often used in combination for biplane quantitative approaches to left ventricular function.
- This view also permits the left atrial appendage and coronary sinus (figure) to be recorded in some patients.

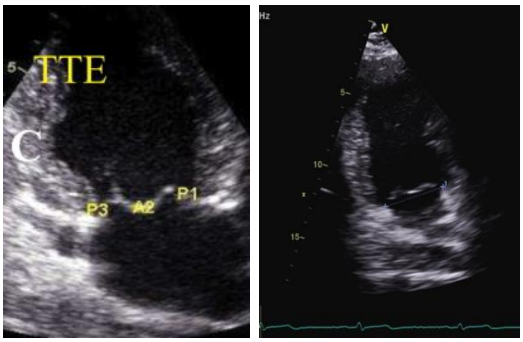

- Assess contractility of LV segements (3 anterior segments, 3 inferior segments & apex). You may consider reducing the depth to concentrate on the LV.
- Apply colors Doppler to check for MR. Then, increase the depth so that LV occupy the whole screen for better focus on wall motion.
- Apical 2C may display the MV bi-commissural view. A modified apical 2C can be used to measure the anatomical commissure–commissure annulus. This is obtained by rotating from the apical 4C to obtain an even distribution of $P_1A_2P_3$ scallops.

APICAL LONG AXIS (3 CHAMBER)

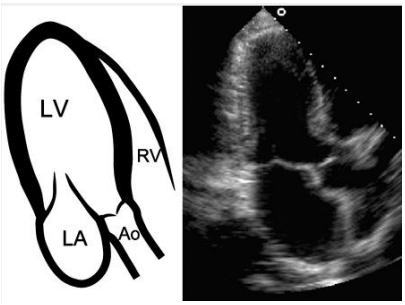

Return the transducer position to the 4C orientation and then rotate clockwise approximately 60 degrees, to record the apical long-axis view, characterized by the presence of both the mitral and aortic valves in the same plane. The transducer groove (or dot) should point toward right shoulder now. This is a similar plane to the PLAX except that it is recorded from the apex. An important difference between the two long-axis views is the relationship between the endocardial surface and the ultrasound beam. From the parasternal view, the endocardium is roughly perpendicular to the beam, thereby facilitating endocardial definition. From the apical window, the left ventricular walls and the ultrasound beam are more parallel, which in some cases results in endocardial dropout and poorer visualization of wall motion. LV segments seen in Apical LAX (3C) view are:

- Basal and mid anteroseptal → apical septal/anterior
- Basal and mid inferolateral → apical lateral
- Apex.

An advantage of this view is its utility in detecting and quantifying aortic valvular and subvalvular obstruction, including hypertrophic cardiomyopathy as it may provide better Doppler alignment than 5CV. LVOT diameter may be measured from 5CV or 3CV at similar level as LVOT PW Doppler velocity trace obtained, typically 0.5-1.0 cm below AV annulus in calcific AS, and just at AV annulus level in bicuspid AS.

SUBCOSTAL 4 CHAMBER

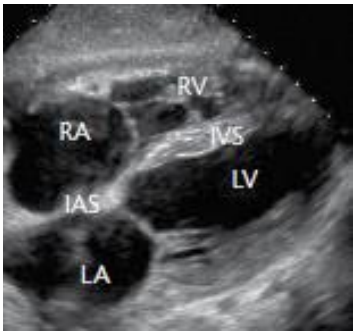

- Ask the patient to lie supine with his arms by his sides ± his knees bent to help relax his abdominal wall. The probe should be placed just below the xiphisternum and held at angled up towards the heart (30-60 degrees to the skin), with the 'dot' to the patient's left (at 1-2 O'clock)
- Ask the patient to breath in slowly and hold when the figure is optimum. Adjust the depth ± the width so that all 4 chambers are fully visualized and occupy the whole screen. RA and RV should be on the top of the screen while LA and LV on the lower part.
- In this view the ultrasound beam is oriented perpendicular to the long axis of the left ventricle and thus often provides better endocardial definition of the ventricular walls in comparison to the corresponding apical view. However, because of the position of the transducer relative to the cardiac apex, foreshortening or inability to visualize the left ventricular apex is more likely. Nevertheless, the apices of the two ventricles can be visualized by tilting the plane slightly toward the patient's left.

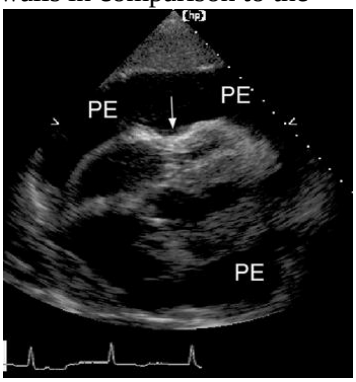

- The proximity of the right ventricular free wall to the transducer also makes this view ideal for assessing right ventricular free wall thickness and motion and may be helpful in evaluating abnormal wall motion in patients with suspected pericardial tamponade.
- Because of the orientation of the interventricular and interatrial septa relative to the scan plane, this view is particularly useful to examine these structures and to search for septal defects.
- The atrial septum can be seen in its entirety from the subcostal position, unlike the parasternal and apical positions in which dropout of echoes of the atrial septum in the region of the fossa ovalis may be noted. In adult patients, this is frequently the only echocardiographic view that visualizes the superior portion of the atrial septum, permitting sinus venosus defects to be detected.
- Apply color Doppler to check for PFO, ASD or VSD; if any present interrogate the flow with PW Doppler placing the sample volume on the jet to specify the direction of the flow.

SUBCOSTAL SAX

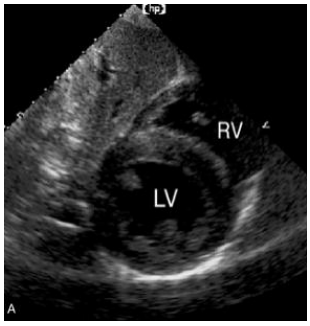

- From the four-chamber view, rotate the transducer 90 degrees anticlockwise and tilt the plane inferiorly gradually to record a series of short-axis images moving from base to apex. Figure A demonstrates a short-axis plane at the papillary muscle level.
- Tilt the plane superiorly to obtain view of the RVOT, pulmonary valve, and proximal pulmonary artery (Fig. B). This is a useful alternative to the parasternal short-axis view for the assessment of these structures. The orientation of blood flow parallel to the ultrasound beam facilitates quantitative Doppler analysis.

SUBCOSTAL IVC

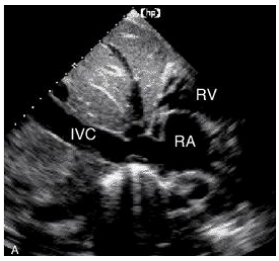

- Tilt the transducer anticlockwise so that its groove points toward the patient's right flank. With this position, the liver parenchyma, hepatic vessels, and inferior vena cava are visualized.
- Measure the diameter of IVC at its widest dimension at the entry to RA and check its response to “sniffing”. M-mode may help in measuring the diameter at end-inspiration and end-expiration to evaluate the respiratory variation.

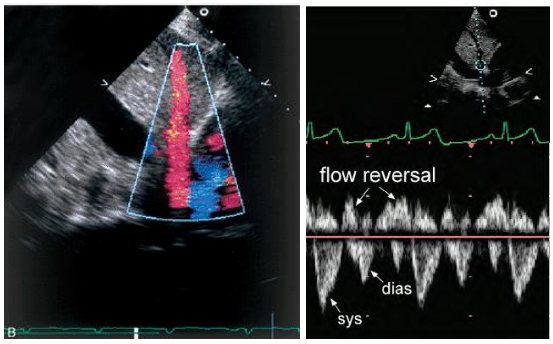

- **Hepatic vein flow** is recorded using pulsed Doppler imaging. To record flow in the hepatic veins, it is first necessary to visualize the inferior vena cava, a few centimetres below the diaphragm. Then, using colour Doppler imaging, the liver can be interrogated until a vein is identified oriented parallel to the ultrasound beam. PW Doppler imaging can then be used to record flow velocities within the hepatic vein. Because hepatic vein flow and IVC flow are similar and because it is generally easier to align the Doppler signal with a hepatic vein, this is both useful and practical. For maximal value, hepatic vein flow must be assessed in conjunction with the respiratory cycle. Hepatic vein flow is respiratory cycle dependent with increased flow velocity during inspiration and decreased

SUPRASTERNAL POSITION

- Place transducer in the supra sternal notch asking the patient to look up and backward. It is sometimes necessary to elevate the shoulders using a pillow to tilt the head backward.
- Transducer groove should face one O'clock directing the ultrasound beam toward the left chest and posteriorly. Aortic arch with its branches can be seen in the majority of patients. Increase the depth and adjust gain accordingly. Record. Apply color Doppler window over the descending aorta. This can useful in assessing the severity of aortic regurgitation and in ruling out coarctation of aorta. CW and PW Doppler may be further required accordingly in these conditions. The quality of the suprasternal images is usually sub-optimal in defining atherosclerotic plaque burden in the arch as compared with TOE in cases of stroke for example. However, it's good practice to check the aortic arch at the conclusion of transthoracic echo study.

CAROTID DOPPLER ULTRASONOGRAPHY

Role of Carotid Ultrasound

- To examine the extra-cranial cerebrovascular supply for signs of arterial abnormalities that may be responsible for cerebral or vascular symptoms.
- Also for preoperative screening of patients with known cardio-vascular risk factors

Although Doppler equation demands an angle of incidence between the ultrasound beam and the vector of blood flow of no more than 20°, for the carotid arteries this limitation is not so strict due to their anatomic location. An angle < 60° is usually acceptable for proper non-invasive haemodynamic assessment of a stenosis.

A Carotid ultrasound series should include the following images:

- Common Carotid artery in B mode - long, trans
- Common Carotid artery with colour & spectral Doppler
- External Carotid artery origin B mode
- External Carotid artery origin with colour & spectral Doppler
- Internal Carotid artery origin B mode
- Internal Carotid artery origin with colour & spectral Doppler
- Vertebral artery spectral Doppler showing patency and flow direction
- Document:
  - The normal anatomy.
  - Any plaque found (in 2 planes).
  - All peak systolic and end diastolic velocities

The ECA has small branches (usually the thyroglossal artery). The ECA also usually has a smaller diameter, arises laterally and has a higher resistance waveform (i.e. lower diastolic flow than a normal ICA). A normal ICA will have no branches and usually a lower resistance waveform.