1. INTRODUCTION

Coronary Anatomy:

- **LAD** courses along the anterior interventricular groove, supplying numerous septal perforators to the septum and a variable number of diagonal branches to the anterolateral wall of the left ventricle, and usually continues to the apex.
- **Clinical division of LAD:**
  1) Proximal segment: from ostium to S1
  2) Mid segment: from S1 to D2
  3) Distal segment: from D2 to end
- **The CX** courses along the left atrioventricular (AV) groove, providing a variable number of marginal branches to supply the lateral wall.
- **The CX** continues in the AV groove for a variable distance. In patients in whom the CX is dominant (8%), the CX reaches the posterior interventricular groove and gives rise to a posterior descending artery (PDA) branch.
- **Clinical division of the LCX:**
  1) Proximal segment: from ostium to OM1
  2) Mid segment: from OM1 to OM2
  3) Distal segment: from OM2 to end
- **The RCA** courses along the right AV groove, providing atrial branches (to the right atrium) and marginal branches (to the right ventricle). A conus branch originates as the first branch from the proximal RCA to supply the right ventricular outflow tract; about half of the time, this branch has an ostium that is separate from the RCA ostium. It is usually unnecessary to visualize a separate conus branch, unless collaterals to the LAD are suspected.
- **The RCA** gives off a branch to the sinus node about 60% of the time (otherwise a left atrial branch of the LCX serves this function). The first major branch the distal RCA gives off is the PDA, in a right dominant system (85%).
- **The PDA** courses along the inferior interventricular groove, providing septal perforators to supply the inferior septum. After giving off a PDA, the RCA continues as a posterolateral segment supplying a variable number of posterior ventricular branches. From this posterolateral segment, the RCA usually (90% of the time) provides a branch to supply the AV node.
- **Clinical division of RCA:**
  1) Proximal segment: form the ostium to first RV branch
  2) Mid segment: from first RV branch to acute marginal branch
  3) Distal segment: from acute marginal branch to crux

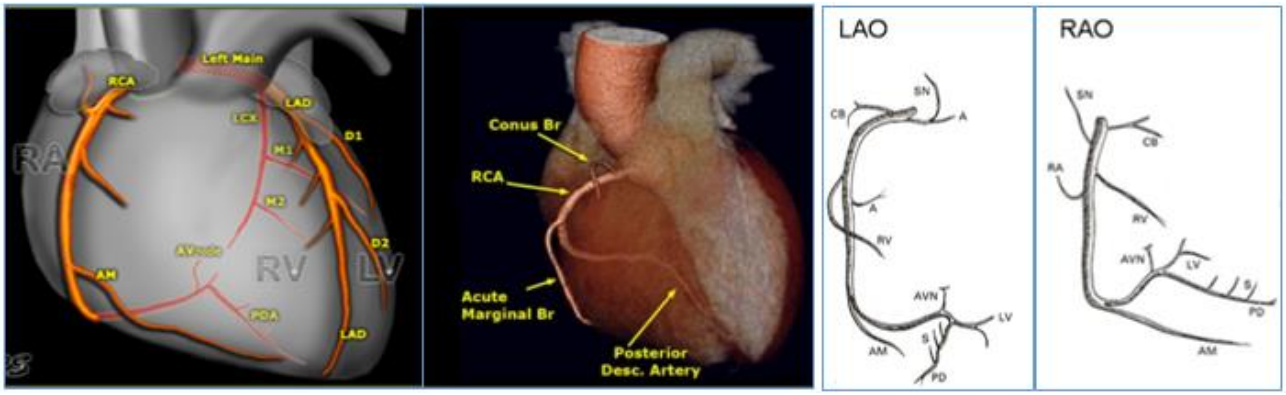

Catheters:

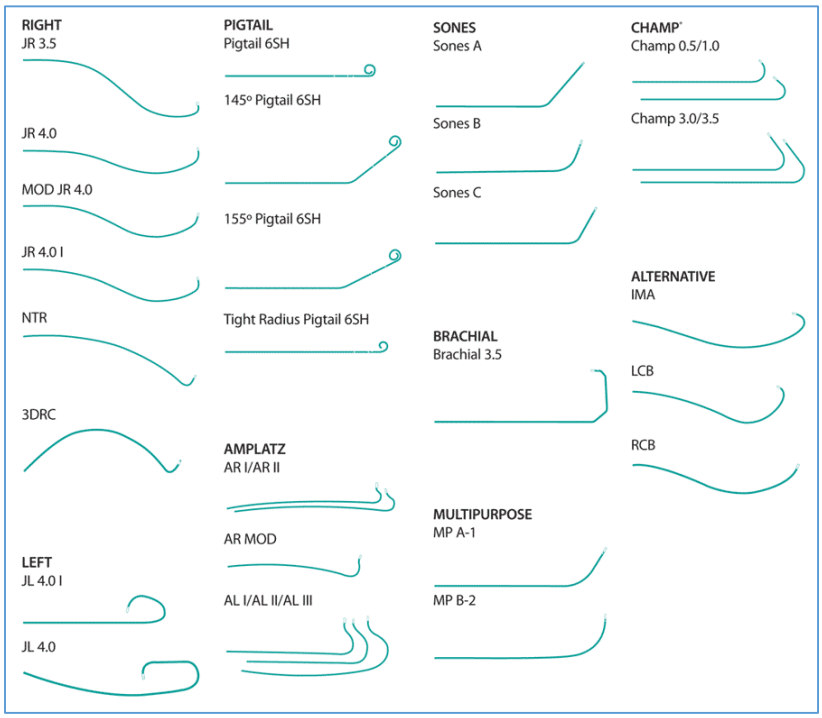

Basic principles of angiographic Views:

- The spine (and the catheter in the descending Ao) are on the left of the screen in an RAO view and on the right of the screen in an LAO view. The diaphragm is brought into the field in the cranial views.

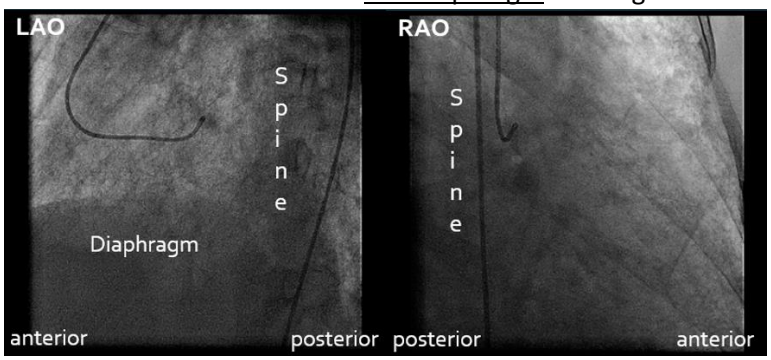

- In the LAO projection, The heart is seen more on end (shorter and rounder), while in the RAO projection, the heart is seen in profile (longer with the tip extending to the left chest wall).

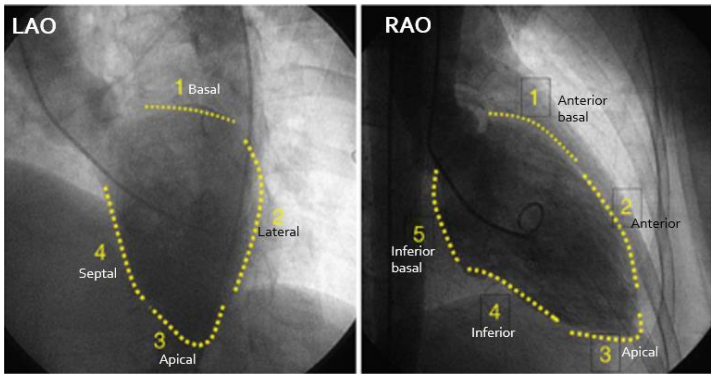

- The diagonal and OM branches tend to move in synchrony, because they supply the lateral aspect of the heart.

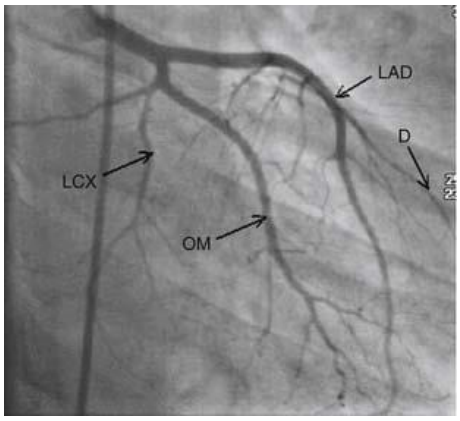

- In the RAO view, a diagonal branch, and not the LAD itself, usually lies on the heart border RAO/LAO angulation prevent the spine and catheter shaft from overlapping the arteries
- Cranial angulation prevent foreshortening of LAD and distal branches (best used to see the LAD and diagonals)
- Caudal angulation prevent overlapping of proximal vessels and foreshortening of CX (best to see the CX and LM)
- It is best to wait for two to three systolic cycles and focus on proximal vessels before panning down the length of the artery of interest. It is important to pan to look for collaterals.
- Atrial kick is noticed in the atrial branches from either the CX or RCA and also in the AV continuation of the CX that lies in the AV groove.

Summary of angiographic views in our institution: Femoral, LC, RC, Grafts, LV, Aorta

- **Femoral shot**: in RAO 30 with Mag 25
- **Left coronary**: screen into position in PA with Mag 25 for engagement then Mag 20 for acquisition
  → shallow RAO 5-10 (LM shaft & proximal vessels)
  → LAO Cranial 40/20 (LAD)
  → LAO Caudal 40/30 (spider) (LM bifurcation & CX)
  → RAO Caudal 30/20 (CX)
  → PA Cranial 40 (LAD)
- **Right coronary**: screen up to arch in PA with Mag 25 → LAO 30 with Mag 25 for engagement, then Mag 20 for acquisition
  → LAO 40 (ostium, proximal & mid-RCA and bifurcation)
  → RAO 30 (mid-RCA & PDA)
  → Cranial AP or LAO 20/20 (PDA & PLV)
- **Bypass grafts:**
  - SVG to RCA/PDA is cannulated in **LAO** then viewed in LAO & RAO (similar to RCA)
  - SVG to LAD/diagonal is cannulated in **RAO** then viewed in RAO & LAO.
  - SVG to CX/OM is cannulated in **RAO** then viewed in RAO & LAO.
  - LIMA to LAD is cannulated in **AP** then viewed in AP, LAO & RAO
- **Left Ventriculography**: screen into position in PA with Mag 25 → RAO 30
- **Aortography**: screen into position in PA with Mag 25 → LAO 40
- **General Rules:**
  - Mag 25 is the standard Mag except for coronary acquisition
  - Mag 20 for both LC and RC acquisition
  - AP is the standard view for any catheter ascent to the arch & for engagement of LC & LIMA
  - LAO for engagement of RCA, SVG to RCA and aortogram
  - RAO for femoral, LV and engagement of SVG to LAD/diagonal/OM

Contrast injection:

- Injection of contrast should be gentle and pressure gradually increased (" ramping"). Enough contrast should be injected to opacify the entire coronary artery and ensure reflux into the aorta (usually about 8 mL for the LCA).
- Injection force should be forceful enough to prevent "streaming," the inadequate opacification of coronary arteries that can create the illusion of stenoses.
- Volume and rate of infusion for selective coronary angiography (using Bracco set): 8 ml @ 3 ml/sec
- Contrast volume and rate of infusion for LV angiogram (using Bracco set): 30 ml @ 12 ml/sec
- Contrast volume and rate of infusion for Aortogram (using Bracco set): 40 ml @ 20 ml/sec

Quantification of coronary stenosis:

- It is important to always obtain at least two perpendicular views of each coronary artery lesion.
- Lesions are generally classified as severe if 70% or more are in the LAD, LCX, and RCA or 50% are in the left main artery. When measuring the size of vessels and stenoses, it is useful to note that a 6F catheter has an external diameter of 2 mm.

2. PATIENT PREPARATION & LABORATORY ATMOSPHERE

- **Coagulation:**
  - Warfarin: to be discontinued 72 hours before the procedure (INR of < 1.8 is a cuff-off)
  - Heparin: to be discontinued 2 hours before the procedure
  - Platelet count of < 50,000 increases the risk of bleeding
- **Active infection** is a reason to defer elective cardiac catheterization. **Local skin infection** at the site of the potential puncture is also undesirable.
- **Severe anaemia, hypokalaemia, or hyperkalaemia** should be corrected before the elective procedure.
- **Recent CVA** (< 1 month) is a relative contraindication to cardiac catheterization
- **A synthetic vascular graft** that is older than 6 months is not a strict contraindication to catheterization.
- An arm approach obviates the need to cross the **AAA** altogether.
- **Metformin** should be stopped at the time of the procedure, although the risk of lactic acidosis is extremely low in a patient with normal creatinine. There is no evidence that withholding metformin for 48 hours before a contrast procedure in patients with normal renal function provides any clinical benefit.
- If the patient is using **long-acting insulin**, the dose should be reduced by 50% and the patient should not eat breakfast.
- **Pre-procedural fasting** is the rule. Sedative agents may impair airway reflexes, placing the patient at increased risk for aspirating gastric contents. The patient should be NPO for solids and non-clear liquids after midnight or at least 8 hours before the start of the procedure. Clear liquids may be appropriate 1 to 3 hours before the procedure, depending on the type and dose of the sedative agent to be used. A more recent suggestion to avoid dehydration and increased chance of contrast-induced nephropathy is to permit or encourage the patient to drink water before the procedure and confine the NPO orders to solid foods or dairy products before the procedure.
- **Ionic contrast dye** was historically used during most cardiac catheterizations.
- **Non-ionic dye** produces less LV dysfunction, bradycardia, and hypotension, as well as less nausea and emesis. Thus, it is useful in cases of suspected LM stenosis, severe LV dysfunction, and severe AS. Other indications for non-ionic dye are severe renal dysfunction and a reported allergy to contrast dye. Non-ionic contrast is more thrombogenic than ionic contrast. Therefore, it should be used carefully in patients with acute coronary syndromes. Whenever non-ionic contrast is used, 5 IU of heparin per cubic centimeter of contrast should be added.
- **Dye allergy premedication**:
  - Hydrocortisone 100 mg IV + Diphenhydramine 50 mg IV/oral (or Chlorphenamine Maleate 4 mg oral/10 mg IV) one hour before the procedure.
  - Hydrocortisone IV can be replaced with prednisone 50 mg x 3 doses (13, 7, 1 hour before the procedure)
- **Dye allergy treatment:**
  - **Hives or rashes**: Diphenhydramine (or Chlorphenamine Maleate) is usually sufficient. Hydrocortisone is also often given, though its effects may not manifest for several hours.
  - **Oropharyngeal oedema, bronchospasm, or hypotension**: Epinephrine 0.3 mg SC, followed by IV infusion 1 mg over 100 min if symptoms are refractory.
- **Latex allergy precautions:**
  - Patients with latex allergy should be scheduled as the first case of the day to avoid latex dust from previous procedures.
  - The sheath is a source of latex exposure. Therefore, a sheathless approach involving catheter exchanges over a wire is preferred.
- **Sedation/analgesia**: Diazepam 2-5 mg IV, Midazolam 1 to 2 mg IV or Lorazepam 1 to 2 mg IV. Some operators use fentanyl 25 mg IV or morphine 1 to 2 mg IV
- **Contraindications to conscious sedation** include the following:
  - Recent (< 2 hour) ingestion of large food or fluid volumes
  - Physical class 4 (severe systemic disease that is a constant threat to life) or greater

  - Lack of support staff or monitoring equipment
  - Lack of experience/ credentialing on the part of the clinician
- **In the laboratory, communication** should occur quietly and without alarming tones. Patients should be addressed directly, by name, to let them know what their instructions are, as opposed to requests or communications to co-workers.
- When on the catheterization table, **the patient remembers two major potentially painful points** of a case: (1) the initial introduction of the local anaesthetic (and sometimes radial sheath introduction) and (2) any discomfort experienced after the study has been completed. Such discomfort usually occurs while the operator or nurse is holding the femoral puncture site. If the local anaesthetic injection is performed too quickly or if the arterial closure or compression after the procedure is difficult or painful, the patient will remember that the physician who performed the catheterization "hurt me." The period between the two events is often forgotten
- **Radiation Safety:**
  - For all catheterization laboratories, the x-ray source is under the table, and the image intensifier (II) is directly above the patient
  - Radiation badges are worn inside the lead apron and outside the thyroid collar
  - A leaded acrylic shield should be used between the patient and the operator closest to the patient. Standing further from the table also reduces radiation exposure by the inverse square of the distance.
  - Fluoroscopy and, in particular, cine time should be minimized. The image intensifier should be positioned as close as possible to the patient
  - higher magnification should be used judiciously. "Coning down" on a region of interest with the use of collimators
  - In RAO, the contour collimator (called the wedge or shield) should be moved to the upper right of the screen
  - Right anterior oblique (RAO) views produce less radiation scatter for the operator than left anterior oblique (LAO) views.
  - Higher cine frame rates increase radiation exposure. The usual frame rate of cine film is set at 30 frames/ s; in patients with tachycardia 60 frames/ s can be useful. In thin individuals who are bradycardic, the frame rate can be lowered to 15 frames/ s.

3. ACCESS SITE & GUIDEWIRES

In general, femoral access is quicker, easier, but has more complications, and radial access is more difficult, takes more skill and time, but has nearly no complications.

Femoral Access:

- The patient is first positioned appropriately, with the knees about 12" apart.
- The goal is to access the common femoral artery over the mid portion of the femoral head so that there is a hard surface against which to compress the femoral artery when achieving haemostasis.

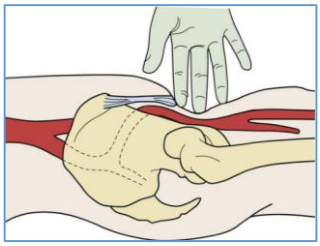

Fig. *Manual compression over the femoral head*

- The mid portion of the femoral head is located approximately 2 cm (finger breadths) below the inguinal ligament. The inguinal ligament is located by palpating the anterior superior iliac spine and the pubis and drawing an imaginary line between them.

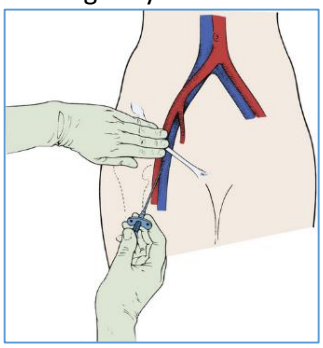

Fig. *Femoral artery (or vein) puncture with needle entering ~ 2 cm below the inguinal ligament and aiming medially toward the umbilicus*

- Fluoroscopy can be used to locate the femoral head. Some operators put the tip of a metal clamp at the inferior border of the femoral head to indicate where they will numb the patient and then angle their needle such that they access the artery approximately 1 cm above this skin entry location.

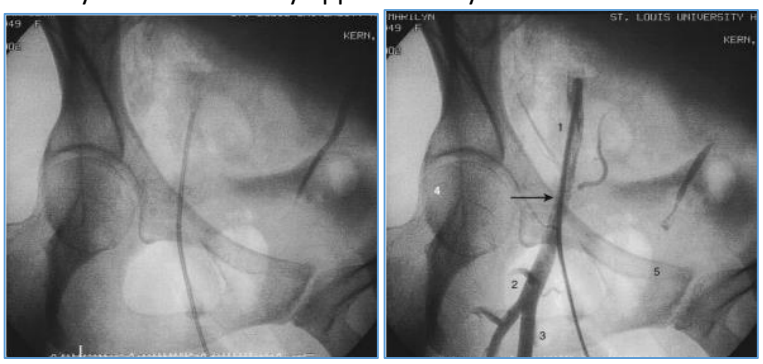

Fig. Femoral artery landmarks. Angiogram of correct positioning of sheath in the femoral artery in the AP projection. 1, Common femoral artery; 2, bifurcation of profunda; 3, superficial femoral artery; 4, midpoint of femoral head; 5, iliac-symphysis pubis ridge (inguinal ligament line). Upper limit of common femoral artery is lower margin of the inferior epigastric artery

- Use of the skin crease is no longer advocated because of its variability, particularly in obese patients.
- Local anaesthesia is given slowly (it hurts less when delivered slowly) while the clinician monitors the HR and watches for signs of a vagal reaction (nausea, light-headedness, and yawning).
- With a 25-gauge needle, the skin is infiltrated superficially with 1% lidocaine 1 cm below the desired arterial entry site. This point is the skin entry site. In obese patients with thick subcutaneous tissue, the entry site should be slightly lower to ensure a needle entry angle of 45 degrees or less. Next, with a 21-gauge needle, further

introduce 6 to 10 mL into the deep tissue planes on each side of the artery. During lidocaine infiltration, palpate the arterial pulse with the middle and index fingers to avoid accidental puncture of the artery and ensure infiltration of tissue above and around the artery.

- Inserting the needle first to the deepest level desired and then continuing infiltration at several more shallow layers may decrease the patient's discomfort. Local anaesthesia should cover the whole depth of the expected skin-to-artery path. Give sufficient lidocaine (15 to 20 mL) over 2 to 3 minutes for the full anaesthetic effect to take place. Hint: Give lidocaine early and while the anaesthetic is taking effect, other preparations such as connecting tubing and flushing catheters can be completed.
- Some operators perform a small skin incision before inserting a Seldinger needle. Other operators prefer to nick the skin over the entry needle or guidewire after the puncture.
- Once the site is anesthetized, an 18G Cook needle is inserted into the artery. Upon nearing the artery, a side-to-side motion of the needle indicates a position either medial or lateral to the artery. Up-and-down motion indicates correct positioning.
- Once brisk arterial blood return is established, a 0.035" J-tipped 45-cm guidewire is inserted
- In the case of a very vertical entry into the artery, as is sometimes encountered in obese patients, lowering the needle hub several millimetres may improve the artery and needle tip alignment and permit easier guidewire passage.
- The wire should move without resistance. If the operator encounters resistance, pull the wire out and confirm that pulsatile blood returns. If you keep on pushing, you can go sub-intimal or create a dissection.
- Sometimes the needle tip partially penetrates the posterior wall. In this case, there is good blood return, but the wire cannot be advanced because it is directed into the posterior wall of the artery rather than the arterial lumen. Withdrawing the needle 1 to 2 mm usually solves this problem. Move the needle hub a few millimetres laterally or medially, after which the guidewire is slowly re-advanced. It is important not to move the needle hub excessively in either direction, which could slice the arterial lumen.
- If it is not possible to advance the wire or if the needle comes out of the artery, withdraw the needle from the skin and apply pressure over the puncture site for at least 2 minutes to ensure haemostasis. Repeat the procedure using a slightly different angle or direction.
- If it is still not possible to advance the wire, then repeat the procedure using a Wholey wire and make sure that you can get it all the way into the aorta in order to be certain that, first, you are intraluminal, and second, that the patient doesn't have an occluded common iliac. For access problems, don't use any other wire. Many people like to use the Glide-wire (Terumo), but it's a hydrophilic wire and shouldn't be used for access, because as you are pulling the wire back, it can get ensnared with the Cook needle at the tip.

Guidewires:

- For general access, use the standard J tip wire that comes in the sheath packet.
- If iliac tortuosity is present and causes inability to advance J tip wire, a Wholey wire or the hydrophilic Terumo glide-wire can be used to get catheters up the aorta.
- If marked iliac tortuosity is present and causes inability to torque catheters:
  - A long sheath can be used to straighten out the iliac vessel.
  - Catheter exchanges over a long (300 cm) stiff exchange guidewire may be required to avoid undue prolongation of the procedure by repeated attempts to advance wires across tortuous atherosclerotic segments cranial to the sheath.
  - It might be necessary to advance a catheter close to (within several centimetres of) the guidewire tip in order to increase the torque control of the guidewire.
  - A catheter (**JR or MP**) can also be used to change the direction of the guidewire tip.
- Problems with catheter engagement due to tortuous iliac artery may be partially overcome by:
  - Keeping the 0.035-inch J-tipped guidewire in the catheter after advancing the catheter to the central aorta and manipulating the catheter with the wire in place to engage the coronary artery.

- In some cases, an extra-stiff (Amplatz-type) guidewire can straighten tortuous vessels, but vessel folding and kinking at the curves may cause pain.

- In the presence of a tortuous iliac artery, catheters can become kinked when attempting to rotate them into the RCA ostium. This is recognized by dampening or even complete loss of the pressure waveform. If this occurs,
  1) The operator should rotate the catheter in the opposite direction (usually counterclockwise) in an attempt to "unkink" the catheter, then
  2) Place a stiff 0.035" wire (Amplatz, SupraCor, or other) through the catheter into the aorta and then remove the catheter & change the short sheath for a long (45 cm) sheath.
- Remember: Wire contact with blood forms thrombi despite anticoagulation. Limit wire-loaded catheter manipulations to 2 to 3 minutes, maintain adequate ACT, and use meticulous wire wipe and sheath flush techniques.

Radial Access:

- To obtain vascular access from the radial site, either the Allen test or the Barbeau test should be performed prior to radial artery catheterization.
- The Allen test: The patient makes a fist. The radial and ulnar arteries are occluded simultaneously. When the hand is opened, it appears to be blanched. Release of the ulnar artery should result in return of pink hand color within 8 to 10 seconds.
- The Barbeau test: Using the pulse oximeter on the thumb, the pulse wave is displayed with both arteries open. The radial artery is then compressed and the pulse wave of ulnar flow can be observed (Fig.). Radial artery cannulation can proceed with types A, B, or C but is not recommended for type D.

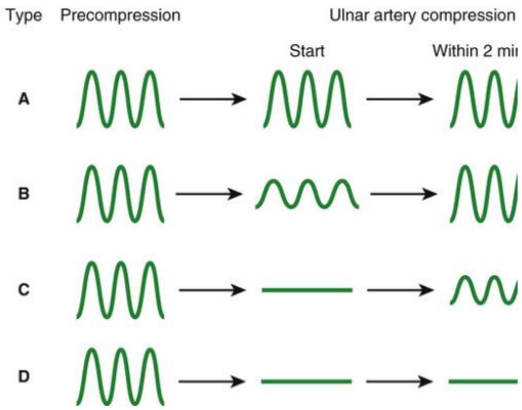

- No significant clinical sequelae after radial artery occlusion occur in patients with a normal Allen or Barbeau test because of the dual blood supply to the hand through the ulnar artery
- Right Versus Left Radial Approach: A right radial approach is typically used because it is the side at which most operators are used to working. However, the left radial approach has been shown to have a shorter learning curve and reduced radiation exposure, and it may be easier for patients who are short (< 165 cm) or elderly (age > 75 years), because these patients develop more tortuosity in their innominate artery. This is also the preferred side for patients who have LIMA graft that must be cannulated.
- Patient Preparation: The patient's arm is abducted at a 70 ° angle and the wrist is hyperextended.
- Large amounts of injected lidocaine may obscure the pulse and make cannulation more difficult.
- Nitroglycerin (300 mcg) and/ or verapamil (2.5 mg) can be injected to decrease radial artery spasm. Heparin 3,000 to 5,000 IU should be considered to avoid sheath thrombosis.

Navigating Up the Arm

Once the sheath is in place, advance the catheter up the arm over a 0.035-inch guidewire. Generally, a standard J-wire with a very small J curve is sufficient. To minimize radiation exposure, the wire is typically advanced up the arm without fluoroscopy; however, if any resistance is encountered, use fluoroscopy. Usually, if the J-wire will not advance, a Glidewire (Terumo or one of the other coated wires) can be manoeuvred up the arm. With coated wires, caution must be used, because they can go into small branches (and potentially perforate) without the tactile feedback one would get from a standard J-wire. On rare occasions, an angiogram of the arm will be necessary. Once the guidewire has reached the shoulder, fluoroscopy is used to ensure safe passage of the guidewire and catheter into the aortic root. If there is tortuosity or looping in the innominate artery, having the patient take a deep breath can help straighten out the anatomy and ease catheter motion. Negotiating innominate or subclavian artery tortuosity may require particularly shaped catheters coupled with softer/harder guidewires. For small calibre vessels,

tortuosity/ loops, or resistance due to spasm/ atherosclerosis, a technique called balloon-assisted tracking (BAT) can be helpful. This involves dilating a coronary balloon at the distal end of the catheter to create a nontraumatic tip that is more flexible or "pushable." Then, advance the catheter/ guide up the arm over a 0.014-inch hydrophilic coronary angioplasty wire.

How to straighten a loop

1. Cross the loop with floppy wire
2. Cross the loop with 5F JR4 catheter
3. Advance a 0.035'' wire
4. Pull back the catheter

Perforation resolution

Immediate outer compression, Heparin neutralisation and shift to another vascular access
OR
Cross the lesion with a 0.014'' wire and inner catheter compression

4. LEFT CORONARY ARTERY

Cannulation of LCA:

- For the left coronary artery (LCA), the size of the **Judkins left (JL)** catheters ranges from JL 3.5 to JL 6. The left main coronary artery is cannulated, typically with a JL 4 in the AP or LAO projection.
- The catheter tip should be coaxial to the left main coronary artery, meaning that its tip should not be touching the upper wall of the left main coronary artery (consider upsizing the catheter if touching the upper wall of the LM). Care should be taken to prevent the catheter from too deeply engaging " deep-seating"

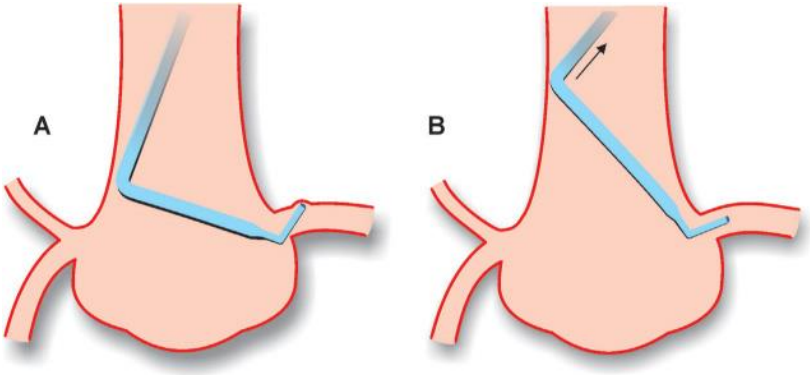

Fig. *In Panel A, incorrectly placed catheter against the vessel wall. Correct placement is shown in Panel B.*

- If the catheter does not engage the left main ostium easily:
  1) A slight clockwise or, more often, a counterclockwise rotation of the catheter hub may help. Counterclockwise rotation moves the JL catheter tip anteriorly and clockwise rotation moves it posteriorly.
  2) In case of partial cannulation, consider checking the catheter location in relation to the LM ostium in the Spider view.
  3) In a larger person or a person with a dilated aorta, In large aortic root, the tip of JL4 catheter ends up above the ostium of the LCA. Clockwise rotation with simultaneous slight advancement of the catheter may work if the tip of the catheter is not far from the ostium. If the tip is too far, rewire the catheter all the way to the left coronary cusp and, after removing the wire, attempt cannulating the ostium on slow catheter withdrawal. Alternatively, the catheter can be upsized to a JL5 or JL6. Occasionally, the JL4 catheter folds into the aorta due to a very large aortic root, and requires straightening and removal over the guidewire.
  4) In a small person or a person with a small aorta, the JL4 catheter tip ends below the ostium. Counterclockwise rotation and slight withdrawal of the catheter often cannulates the ostium. In other instances, the catheter should be downsized to a JL3.5 or JL3.

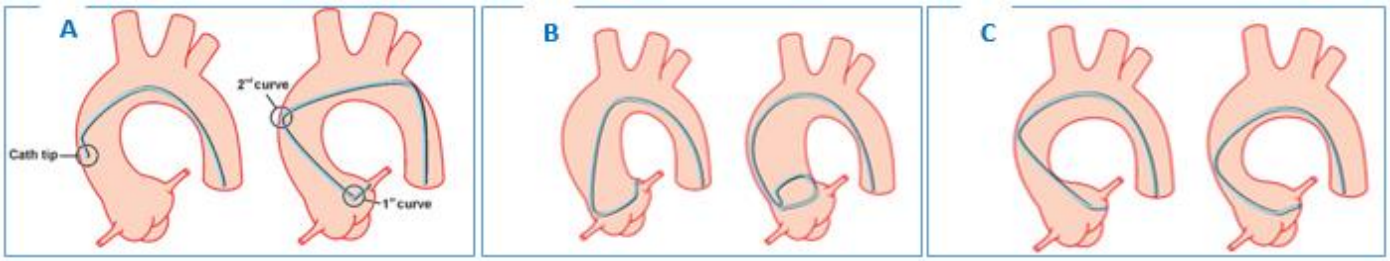

Fig A. normal sized aortic root. **Fig B**. large aortic root. **Fig C**. small aortic root.

  5) The **Amplatz left (AL)** catheters used commonly range in size from AL I to AL III. Avoid aggressively retracting or advancing the catheter tip into the LM trunk in order to avoid injury.

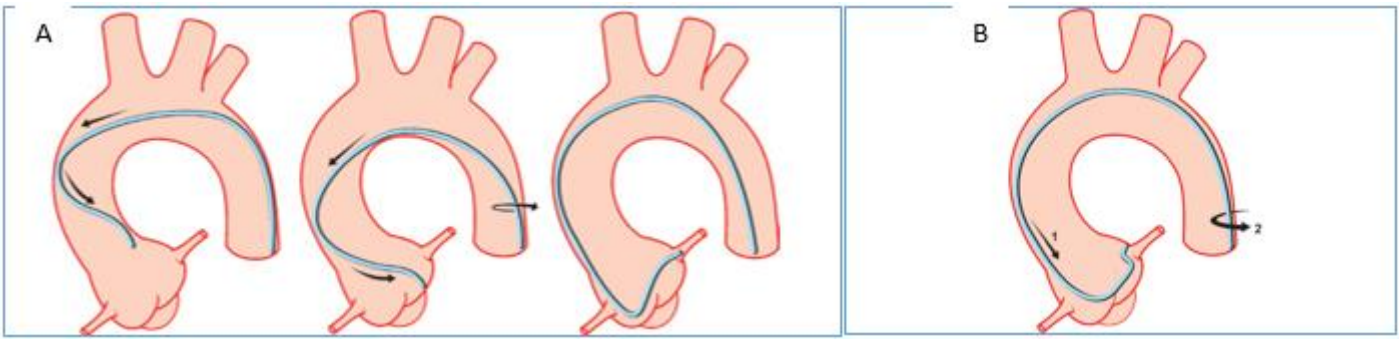

Fig A. The catheter is advanced into the LCC without rotational manipulation of the tip. The secondary curve of the catheter ends up resting in the NCC, while the primary curve and the tip are in the left cusp. Advancing the catheter with mild, counterclockwise torque forces the catheter to move up towards the LCA ostium

Fig B. For removal, the catheter is gently advanced, then clocked or counterclocked to disengage from the ostium in order to avoid dissection of the LM artery

6) Other catheters used include the multipurpose catheters (MP A1, A2, B1, and B2 catheters), which can be used for cannulating the left and right coronary arteries and bypass grafts.
7) For radial approach, JL, AL and TIG catheters are used. TIG catheter can be uses as a single catheter to cannulate both LM and RCA. To cannulate the LM, the catheter may engage from above with slight clockwise or counterclockwise rotation or, more commonly, may require advancement up the left cusp to engage from below with slight withdrawal at the end to achieve a coaxial position, similar to the typical Amplatz technique.
8) If significant left main CAD is suspected, a cusp view (with the catheter placed in the left sinus of Valsalva) can be taken

- The pressure waveform must be observed for damping (a decrease in the systolic pressure) or ventricularization (when the waveform looks like a ventricular pressure tracing), both of which indicate a need to pull the catheter back and also raise the possibility of significant left main CAD. An adequate amount of dye reflux should be seen, unless ostial disease is present.

Basic views of LCA:

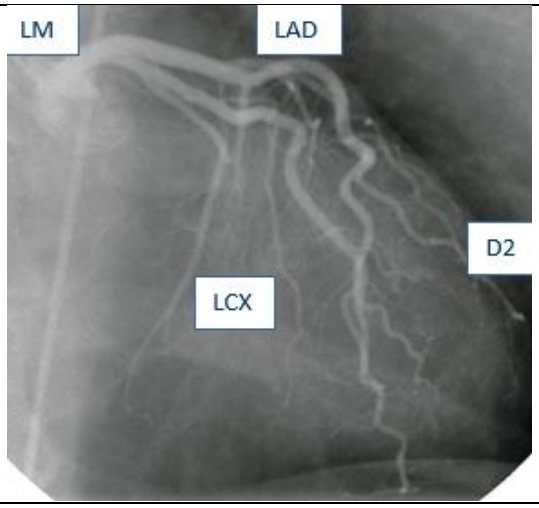	**AP/shallow RAO** ▪ Displays the LM in its entire length. ▪ The proximal LAD and CX are displayed, but the branches are overlapped.

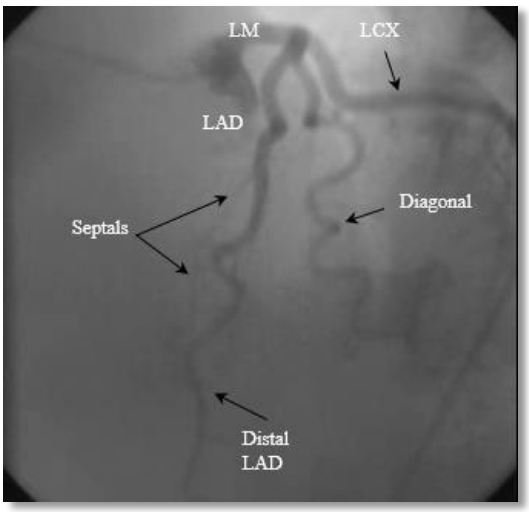	**LAO Cranial 45/30** ▪ Shows the LM (slightly foreshortened) ▪ The LAD and its diagonal branches. ▪ The CX and OM branches are foreshortened and overlapped, although the left PL and left PDA are displayed clearly.
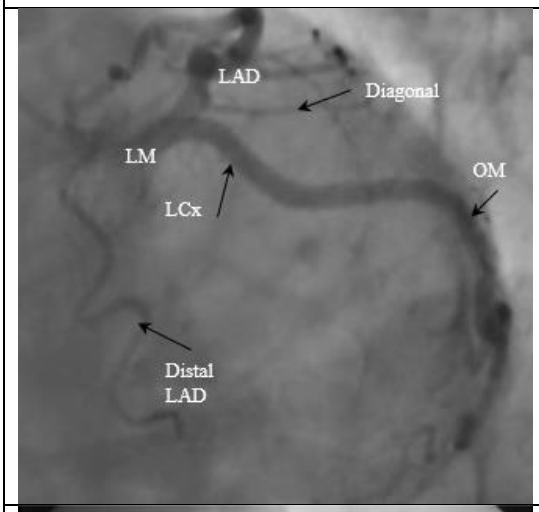	**LAO 45 Caudal 30 (spider view)** ▪ Shows the bifurcation of the LM into CX and LAD. ▪ Proximal and mid CX are usually seen clearly with the origins of OM branches. ▪ LM stem is foreshortened and LM ostium is partially hidden by the coronary sinus. ▪ The LAD artery is considerably foreshortened in this view.
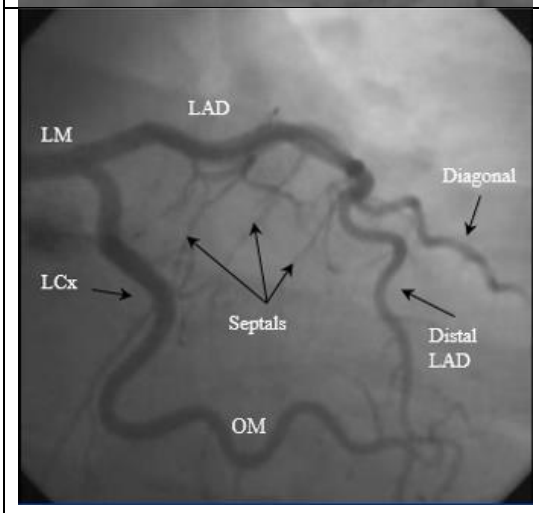	**RAO Caudal 20/20** ▪ The RAO-caudal view shows LM bifurcation, perpendicular to that of the LAO-cranial angle. ▪ The origin and course of the CX/ OM branches, ▪ Ramus intermedius branch, and ▪ proximal LAD segment. The LAD artery beyond the proximal segment is obscured by overlapped diagonals

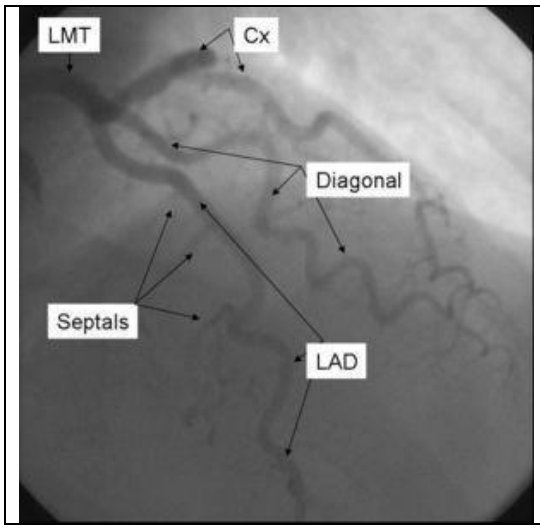	**AP Cranial 0/40** ▪ Separates and elongate the mid and distal LAD

Other views of LCA:

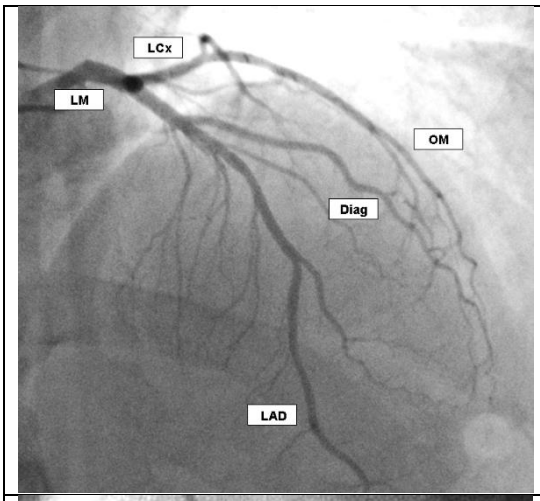	**RAO Cranial** ▪ Origin of diagonal branches along the mid & distal LAD
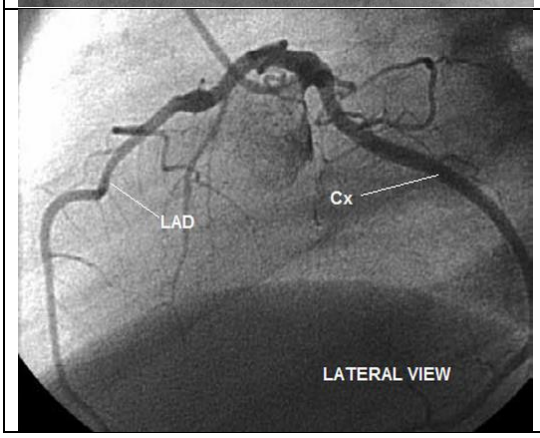	**Lateral** ▪ Best view to show mid & distal LAD. ▪ Diagonals are usually overlapped.

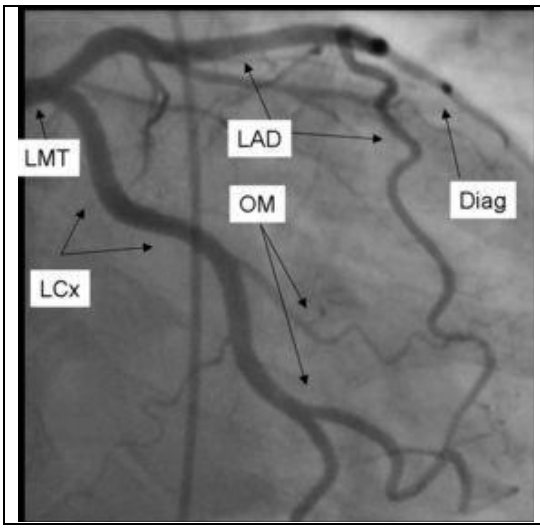

AP Caudal

- LM bifurcation or trifurcation, proximal LAD and LCx, OM and RI

5. RIGHT CORONARY ARTERY

Cannulation of RCA:

- For the right coronary artery (RCA), the **Judkins right (JR)** catheters range in size from JR 3.5 to JR 6. The RCA is cannulated, typically with a JR 4 in the LAO projection
- The RCA is usually located anteriorly in the right sinus, in a position that is lower than the LCA ostium. The catheter must be advanced to the right coronary cusp and then pulled back slowly 2 cm above the AV while applying clockwise torque, causing its tip to move anteriorly and engage. A "push-pull" motion while torqueing the catheter will help transmit the twisting down to the catheter tip.
- The pressure waveform must be observed. Damping signals engagement of the conus branch (which arises separately 50% of the time). Injection of this vessel can lead to ventricular fibrillation.
- Sometimes, if a catheter is tenuously engaged, particularly in the right coronary ostium, a deep breath can dislodge it and should be avoided.
- If the catheter does not engage the RCA ostium easily:
  1) The most common cause of an incomplete LHC is a high and anterior RCA. To locate its ostium, less clockwise torque should be applied to the catheter so that it faces more anteriorly. Then the catheter can search for the ostium superior to the usual location.
  2) If spasm does occur or if an ostial lesion is suspected, a smaller-diameter catheter might be used.
  3) If difficulty is encountered in engaging the RCA because of the orientation of the ostium, a 3DR or a no-torque right catheter (**Williams catheter**) can be useful. Both catheters are designed to be placed above the aortic valve and pulled back without torquing manoeuvres.
  4) For an anterior, posterior or upwardly angle ostium, an **Amplatz right** (AR I to AR III or AR-modified) catheter can be useful. Multipurpose (MP A1, A2, B1, and B2) catheter can be useful for an upwardly angled ostium.
  5) If the RCA cannot be found, a review of left coronary angiography should be examined for unsuspected collateral flow or the RCA potentially coming off the left coronary cusp.
  6) A cusp view can be taken if any of the following conditions is suspected: ostial disease, spasm, selective intubation of the conus, or anatomic variation in the direction of the proximal RCA
- For radial approach, JR, AL (for anterior RCA) and TIG are used. TIG is used as a single catheter to engage both the LM and RCA. To engage the right coronary (after LM engagement), the catheter is slightly withdrawn from the left, rotated just slightly over the valve, and advanced into the right cusp. Once in the right coronary cusp, slow withdrawal with clockwise rotation will engage similar to the Judkins technique.

Basic views of right coronary artery:

- The RCA is usually viewed in LAO and RAO views.

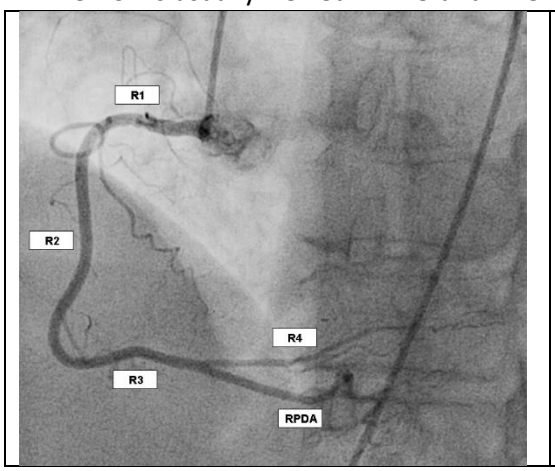

- The **40 ° LAO** view provides a good view of the ostium, proximal and mid segments of the RCA, and bifurcation of the PL & PDA branches.
- if cranial angulation is added, a good view of the PL/PLV (posterolateral. Also called posterior LV) branches.

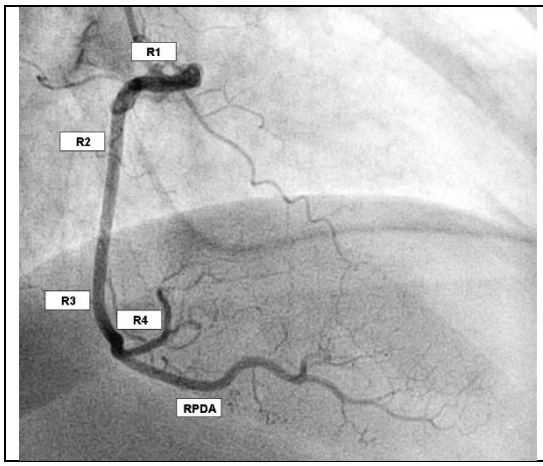

- The **30 ° RAO** view provides a good view of the mid-RCA and the extent of the PDA.
- Cranial angulation can help separate the PDA from the distal vessel.
- In the RAO view, the right atrium and ventricle are separated by the RCA in the AV groove. Thus, atrial branches will be directed toward the atrium and marginal branches will be directed toward the ventricle

Other RCA views:

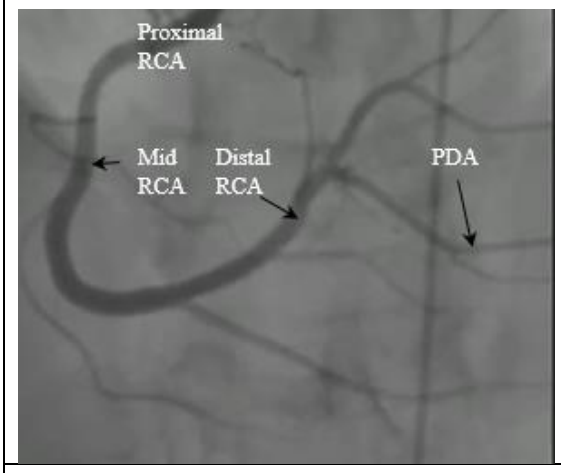

- **AP cranial 30** provides a good view of the distal RCA and its bifurcation (clearly delineates the region of the crux cordis and lesions of the PDA or PL/PLV branches and is more suitable for angioplasty)

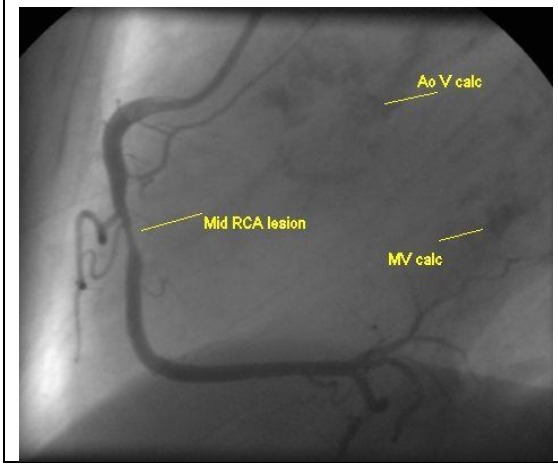

- **Lateral** offers an excellent look at the mid RCA, free of the excessive motion seen when this portion of the vessel is viewed in the straight RAO projection.

6. CONGENITAL CORONARY ARTERY ANOMALIES

- The most common anomaly is an absent left main coronary artery trunk, often referred to as a "double barrel" LM, in which the LAD and CX have separate dual ostia (incidence 0.47%).
  - If LAD (usually more anterior ad superior) is first cannulated, the catheter should be pulled back into the aorta and rotated clockwise; perhaps with a larger catheter (JL 5), is needed to cannulate the CX (lower ostium needs larger catheter)
  - The converse is true if the CX is first cannulated: counterclockwise rotation, perhaps with a smaller-sized catheter (JL 3.5), is needed to cannulate the LAD (higher ostium needs smaller catheter).
  - It may be difficult to determine whether the left main is short or absent and a LAO caudal projection is usually obtained to show the "double barrel" LM in case of dual ostia.

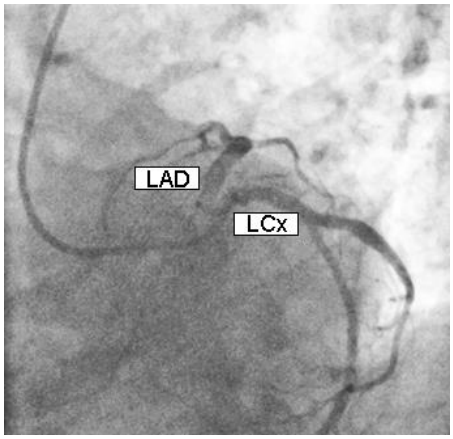

- Other common anomalies in order of importance are the LCX originating from the right sinus of Valsalva (0.45%) and the RCA originating from the ascending aorta above the sinus of Valsalva (0.18%). The RCA originating from the left sinus of Valsalva is the next most common anomaly, originating superior and anterior to the left main (0.13%). The origin of the left main artery from the right sinus is even less common (0.02%), but it can result in sudden death if the left main artery passes between the aorta and the pulmonary artery (extremely rare). The left main artery can also pass into the ventricular septum (most common), anterior to the pulmonary artery or posterior to the aorta. The 30 ° RAO view can help define the relationship between the coronary artery and the great vessels. If the course is septal, septal perforators can be seen originating from the left main. The other coronary anomalies occur much less frequently.
- Aortogram (screen into position in PA & view in LAO 40) is helpful to confirm the diagnosis. The Amplatz (left or right, depending on the cusp of origin) and multipurpose catheters are especially useful in cannulating anomalous coronary arteries.
- Although not truly a congenital anomaly, every angiographer should be aware of myocardial bridging. This is an apparent narrowing of a coronary artery (usually the mid-LAD) that is present only during systole. There have been reports of bridging involving the diagonal branches of the LAD, the marginal branches of the LCX, and the distal RCA. Because the majority of coronary blood flow occurs during diastole, myocardial bridges are rarely pathologic, but there have been patients treated with CABG and, more recently, stenting. Nitroglycerin, by dilating epicardial vessels, can make bridging seem even more pronounced. A phenomenon similar to bridging can occur in hypertrophic obstructive cardiomyopathy, in which septal perforators from the LAD can become obliterated during systole.

7. BYPASS GRAFTS

Cannulation of SVG:

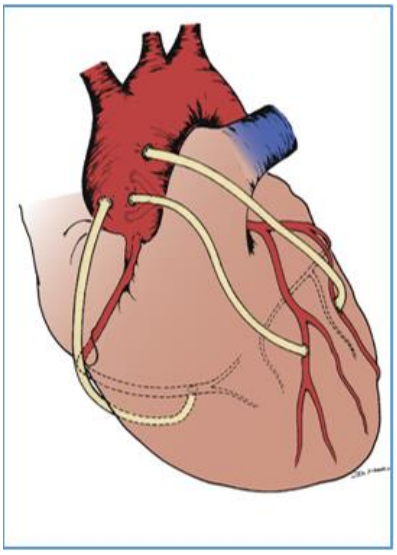

- The grafts are by necessity anastomosed to the anterior surface of the aorta. The graft to the RCA is most anterior and usually the lowest. Grafts to the branches of the LCA usually are inserted in a progressively higher and more posterolateral position.
- The orientation of SVGs from caudal to cranial is usually as follows: RCA, LAD, diagonal , and marginal branches.
- It is the practice of some surgeons to place circular graft markers around the ostia of the vein grafts on the outer surface of the aorta. In the steep LAO projection, the catheter tip should extend beyond the plane of these markers, if the catheter is truly engaged in a vein graft.
- Review of the operative note is mandatory before catheterization to know where grafts were placed. A previous catheterization, if done, should be reviewed.
- Streaming and/or delayed filling on injection of native artery suggests a competitive flow and can be used as indicator of grafting of this native artery if operative notes are not available.
- Aortogram is helpful to localize ostium of missed grafts.

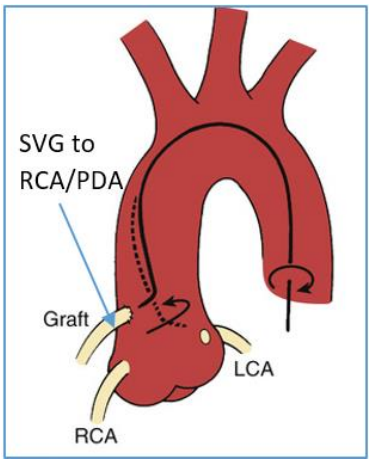

- **For RCA grafts**, the **JR4** is pulled back (from the ostium of the RCA) in the **LAO** projection.
- Often, this graft has a steep downward orientation from the aorta. In this situation, a multipurpose (**MP1**) catheter can be useful in engaging the graft. Alternatively, a right bypass catheter (**RBC**) or a right-modified Amplatz (RA mod.) catheter can be useful in engaging the RCA graft.
- The SVG to RCA is then viewed in **LAO & RAO** (similar to RCA). Other views: LAO **cranial** and lateral

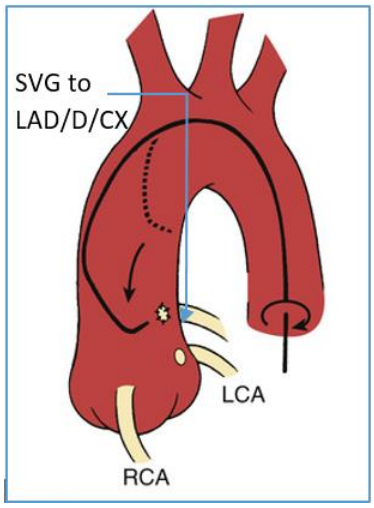

- **For LAD/D grafts**, the **JR4** is further pulled back (from the ostium of SVG to RCA) in the **RAO** projection and rotated clockwise to locate the LAD/D graft. Left bypass (**LBC**), left Amplatz (**LA**), and multipurpose (MP) catheters are all alternative catheters that can be used. The SVG to LAD/D is then viewed in **RAO & LAO**. Other views: LAO **cranial** and cranial RAO
- **For CX/OM grafts** (highest SVG on the aorta), The **JR4** is further pulled back (from the ostium of the SVG to LAD/D) in the **RAO** projection to locate the CX/OM graft. The SVG to CX/OM is then viewed in **RAO & LAO**. Other views: lateral

Cannulation of LIMA

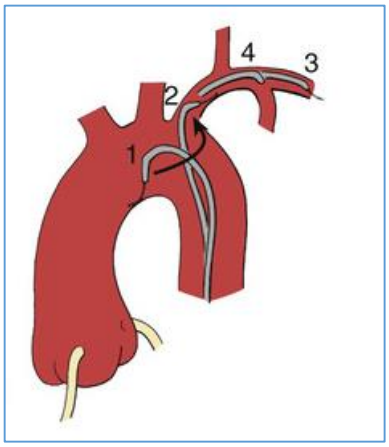

- Catheterization of the LIMA is done either in the **AP** or shallow LAO projection and then viewed in AP, LAO & RAO (or **cranial LAO & cranial RAO**). The **lateral** view is especially useful to visualize LIMA-LAD anastomosis and may help determine whether scar tissue has formed tacking the LIMA to the sternum, a finding important to surgeons planning a reoperation with a second sternotomy)
- First, the catheter (usually a **JR 4**) is positioned by pulling it back from the ascending aorta while applying counterclockwise torque until it enters the left subclavian artery.
- At this point many operators will obtain an angiogram of the left subclavian artery to rule out a stenosis proximal to the LIMA and to give a hint of the angle of take-off of the LIMA.
- J-tipped guidewire (or **Terumo** or Wholey GW in case of marked tortuosity of the proximal subclavian) is then advanced into the subclavian artery, beyond LIMA origin. Next, the catheter is advanced over the wire into the subclavian artery, also beyond LIMA origin. Then the wire is removed, and the catheter is slowly pulled back with a slight counterclockwise rotation until it engages the ostium of the LIMA. Movements around the ostium must be gentle to reduce the risk of dissection of the vessel; frequent test injections are helpful.
- **Turning the head to the left or right and pulling the arm caudally** are manoeuvres that can help engage the LIMA.
- If the ostium points downward at a sharp angle, the **LIMA catheter** is more likely to engage it selectively. The special LIMA catheter provides a slightly different angulation
- If the ostium cannot be engaged successfully, a **nonselective angiogram** can be taken with the tip of the catheter as close to the ostium as possible. **A blood pressure cuff should be inflated above systolic pressure in the left arm** to facilitate dye movement down the LIMA.
- Any pressure gradient between aortic and subclavian arteries should be noted because a subclavian stenosis with a LIMA can lead to anterior wall ischemia. Subclavian stenosis can be stented with high success and low procedural complication rates.

Cannulation of RIMA: Catheterization of the RIMA is similar to that of the LIMA. The catheter (either **JR 4 or LIMA**) is placed in the **brachiocephalic** trunk by pulling it back in the aorta while applying **counterclockwise rotation**. The **wire** is advanced into the right subclavian artery. Care must be taken to avoid the right carotid artery. The wire is removed and the catheter is **pulled back** until it engages the ostium of the RIMA.

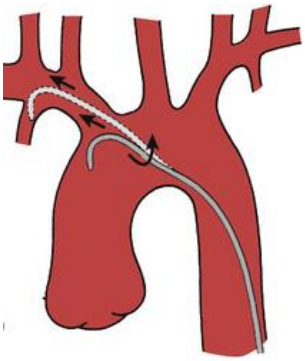

For bypass graft cannulation from radial approach (the ipsilateral radial artery is used if the mammary artery has been utilized as a conduit), the TIG catheter can be used as a single catheter to engage all grafts, as well as the native coronary arteries. If both LIMA and RIMA are used, the contralateral IMA can be engaged from the radial artery. In this situation, the patient would be most comfortably approached from the right radial.

An IMA catheter will allow for right IMA injection and can then be advanced into the descending aorta over a 0.035-inch wire. The catheter can then be oriented to allow passage of a 0.035-inch hydrophilic wire into the left subclavian, axillary, and brachial arteries. At this point, inflating the brachial blood pressure cuff will provide enough support on the wire to allow the IMA catheter to be advanced into the subclavian artery, and the left IMA can be engaged in the usual fashion.



SVGs from the aorta are typically best approached via the left radial, and most commonly, an AL or JR catheter can be used to reach all the grafts. In some cases, a multipurpose catheter may be helpful, specifically when engaging an inferiorly oriented graft to the RCA. Specialty catheters designed specifically for use via the radial approach are illustrated in the figure: Kimny (A), Tiger (B), Ikari left (C), Ikari right (D).

8. LEFT VENTRICULOGRAPHY & AORTOGRAPHY

Crossing the aortic valve:

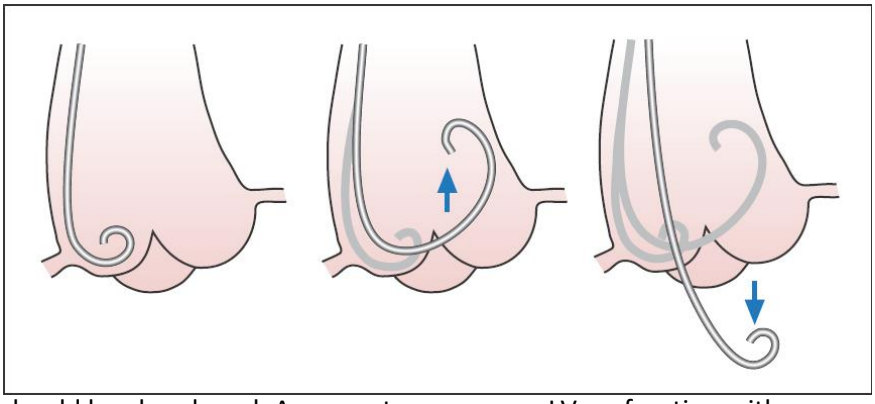

- The pigtail catheter is most commonly used to cross native aortic valves. Tissue valves can also be crossed, but crossing mechanical valves (e.g., St. Jude, Björk-Shiley, and Medtronic-Hall) risks catheter entrapment and is best avoided.
- The practice of end-hole ventriculography through JR or MP catheter with a hand injection is considered inappropriate technique that should be abandoned. An operator can cause LV perforation with an end-hole catheter (e.g., an MP catheter) when the tip is against the LV wall and contrast is injected directly into or through the myocardium, followed by tamponade and cardiac arrest. Hand injection often results in an inadequate and nondiagnostic study.
- The catheter should be made to loop above the aortic valve. When pulled back very slowly, the catheter should give in (can be facilitated by asking the patient to take a deep breath and hold it and the catheter can then be rapidly advanced into the left ventricle during systole. Supporting the catheter by parking the guidewire in the distal segment of the ascending aorta may help this procedure. Sometimes the guidewire itself (supported & directed by the catheter towards the AV) may be useful in crossing the valve (MP or AL1 may be used for this purpose in difficult cases), and then the catheter is simply advanced over the guidewire into the left ventricle.

Left ventriculography:

- The pigtail catheter is positioned in the midcavity of the left ventricle. The pigtail catheter should look like a "6" in the RAO projection.
- If the pigtail catheter twists with each beat, this indicates that it is caught in the mitral valve apparatus and needs to be repositioned.
- First, the left ventricular end-diastolic pressure (LVEDP) should be measured on a 40 scale. In patients with an elevated LVEDP (> 25 mm Hg), a left ventriculogram is generally contraindicated. If the decision to proceed with the left ventriculogram is made, sublingual Nitroglycerin should first be given to lower the LVEDP. With more moderate degrees of left ventricular dysfunction, non-ionic dye, which is less of a myocardial depressant, can be used. Digital subtraction can be used instead of cinefluoroscopy to obtain the left ventriculogram. This allows a smaller amount of contrast to be used. With digital subtraction, the view must be carefully centred because panning is not possible.
- The left ventriculogram is best avoided in patients with critical aortic stenosis, significant left main artery disease, or severe left ventricular dysfunction (LVEDP > 35 mmHg).
- Contrast volume and rate of infusion for LV angiogram (using Bracco set): 30 ml @ 12 ml/sec
- The **30 ° RAO** view is used to look at the overall left ventricular function. In particular, the anterior, apical, and inferior walls can be assessed (similar to apical 2 chamber)
- The **60 ° LAO** projection allows evaluation of the septum and the posterior and lateral walls (similar to apical 4 chamber)
- The visual estimate of the LVEF is acceptable. Grading LVEF by 10% variance is probably common (i.e., < 20%, 20% to 30%, 30% to 40%, etc.)

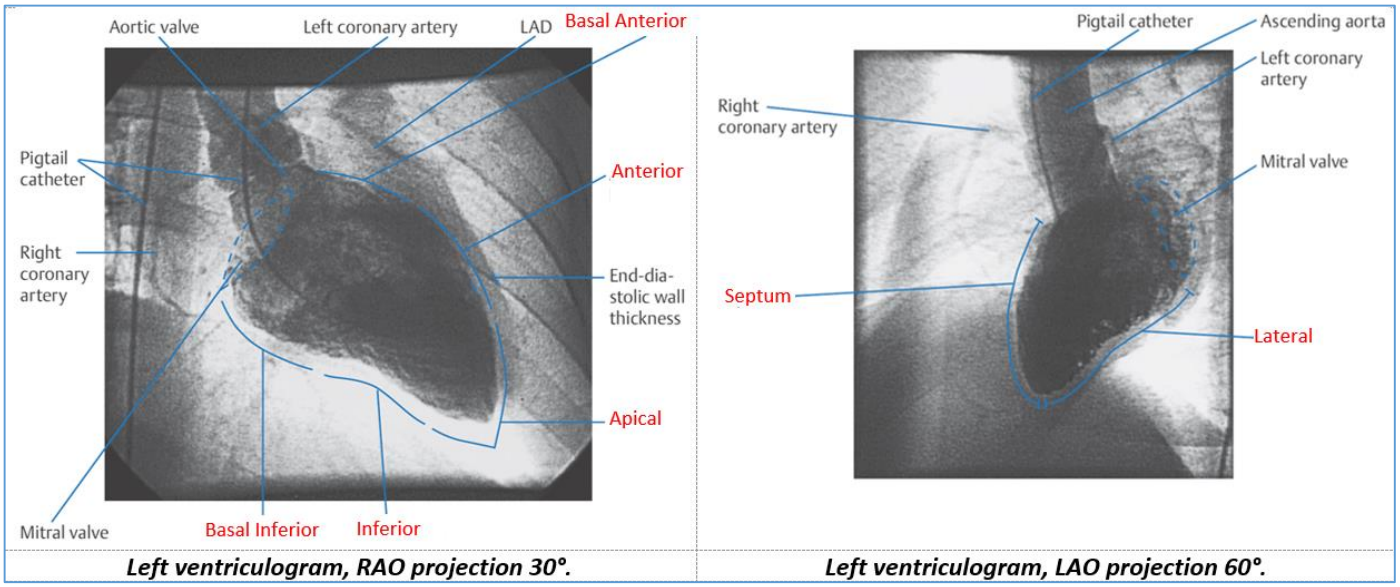

Left ventriculogram, RAO projection 30°. ***Left ventriculogram, LAO projection 60°.***

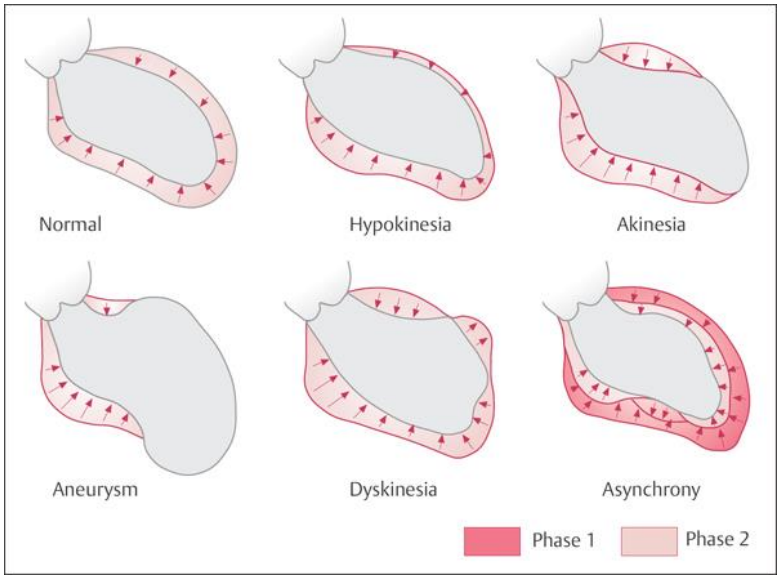

Fig. Wall motion abnormalities of the left ventricle

- The RAO view is also useful to assess mitral leaflet prolapse and MR. The LAO cranial view can also be used to assess MR, and it avoids the overlap of the aorta with the left atrium that occurs in the RAO view.
- MR can be graded on a scale of 1 to 4
  - 1 represents trace MR, with mild left atrial opacification that clears with one beat;
  - 2 represents a mild to moderate degree of opacification, though less than that of the left ventricle;
  - 3 represents moderate to severe opacification of the left atrium equal to that of the left ventricle; and
  - 4 represents complete opacification of the left atrium greater than that of the left ventricle. Panning toward the left atrium may be needed if MR is present.

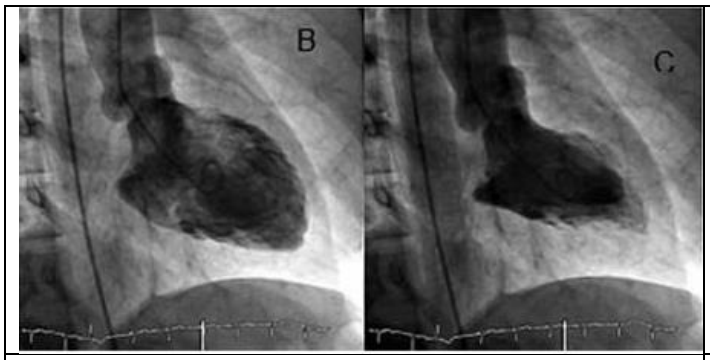	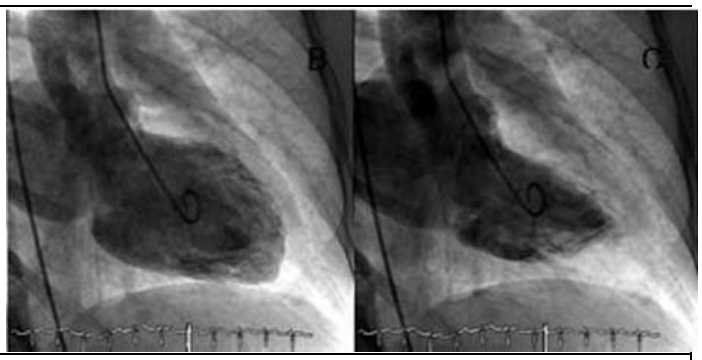
Left ventriculogram, RAO projection 30° at diastole (Left) and systole (Right) with absence of MR	Left ventriculogram, RAO projection 30° at diastole (Left) and systole (Right) with the LA completely opaque due to severe MR.

Aortography is usually performed in the LAO position, with the catheter about 2 cm above the aortic leaflets. Compared with a ventriculogram, a larger volume of contrast is needed to opacify the aorta. **Contrast volume and rate of infusion** for Aortogram (using Bracco set): 40 ml @ 20 ml/sec

9. POST-CATHETERIZATION CARE & COMPLICATIONS

- Bed rest is generally required for 6 hours after a femoral sheath is removed, although some operators require 1 hour for each French size. In fact, 2 hours is a sufficient period of bed rest for 5F sheaths. Two hours of keeping the arm straight is necessary after a brachial or radial procedure.
- After the sheath is removed, haemostasis is generally obtained with direct manual pressure of the fingertips over the pulse, without sterile gauze to obscure the view. Pressure is held for approximately **20 minutes** (about 3 minutes for each French size) until there is no bleeding. Using sandbags over the groin site is discouraged.
- The FemoStop is a pneumatic compression device that can be used for holding pressure in cases of prolonged bleeding. The C clamp is a mechanical clamp that can also be used for holding prolonged pressure. If either of these devices is employed, direct supervision of the patient is required.
- The Angioseal haemostatic puncture closure device can be used to obtain haemostasis in an uncomplicated femoral procedure if an 8F or a smaller sheath was used. Before deploying the Angioseal, it is advisable to obtain an angiogram of the femoral artery (in RAO 30 with Mag 25) to ensure that the entry site of sheath is above the bifurcation of the common femoral artery. It is available in 6F and 8F sizes. A biodegradable collagen plug is deployed at the femoral artery puncture site using a guidewire and special sheath. No manual pressure is required, and ambulation can begin after 1 hour. The disadvantage of this device is the introduction of foreign material that could be a potential source of infection, and repeat arterial puncture cannot be performed at the same site for about 45 to 60 days.

Complications

- There is a 0.1% risk of death from LHC. This risk is substantially higher in patients undergoing urgent catheterization for acute coronary syndromes. In addition, patients with left main CAD, severe aortic stenosis, or severe left ventricular dysfunction are known to be patient subgroups with a particularly increased risk. Advanced age increases the risk of death.
- There is a 0.05% risk of MI from LHC. MI can result from coronary dissection, disruption of a pre-existing atheromatous plaque, and a large air embolus or a thrombus.
- Stroke occurs in 0.05% of catheterizations. There is a risk of stroke from an inadvertent air embolus or thrombus. The presence of aortic atheroma is a risk factor for embolic complications. Dislodgement of atheromatous debris in the aorta can lead to a stroke. **This risk can be minimized by the use of 260-cm exchange wires for catheter changes in patients with known severe aortic disease.**
- Engagement of the coronary arteries can rarely cause dissection. It is most often due to the injection of contrast through a catheter that is not coaxial to the coronary artery, causing rupture of a pre-existing plaque, or placement of the catheter too deeply into the coronary artery (so-called deep throating). Particular caution should be used with Amplatz catheters**.** In cases of left main coronary artery dissection, a stent can be placed emergently and the patient can be placed on peripheral cardiopulmonary support until the surgical team can be mobilized.
- Engagement of the coronary arteries, in particular the RCA, can cause spasm**.** This is best treated with withdrawal of the catheter. Subsequent reengagement and administration of intracoronary Nitroglycerin (100 to 200 µg) may also be necessary for more rapid resolution of spasm.
- Contrast dye can precipitate renal failure in any patient, although certain patients (those with elevated creatinine, diabetes, proteinuria, or dehydration) are at higher risk. Adequate prehydration with normal saline can reduce this risk. The best way to minimize contrast-induced renal failure is to limit the amount of dye used. Using < 30 mL of contrast dye dramatically reduces the incidence of renal failure in even the highest risk patients.
- A risk of ventricular fibrillation (0.5%) exists with catheterization. This rhythm is treated with electrical defibrillation. In particular, over-injection of contrast into the RCA can cause ventricular fibrillation. Contrast dye (less so non-ionic dye) can cause transient bradycardia, best dealt with by having the patient cough and by minimizing the amount of dye injected
- The osmotic load of contrast dye can put a patient with diminished cardiac or renal function into overt pulmonary oedema. In patients with severe cardiac or renal disease, injection of contrast should be limited, and the use of non-ionic, low-osmolar dye should be considered.

- If a patient develops hypotension and/ or bradycardia, a vagal reaction should be considered. It is a common occurrence when local anaesthetic is being administered or when the sheath is being removed. Atropine 1 mg IV should be available and given in these situations. Adequate anaesthesia can help prevent such reactions. In a patient with severe aortic stenosis or left main CAD, a vagal reaction can start a downward spiral that leads to death. Levophed (about 10 µg) should always be available and used immediately in such cases of hypotension.
- Pseudoaneurysms, arteriovenous fistulas, arterial thrombosis, and peripheral emboli are possible vascular complications. Careful technique can minimize these events. In particular, paying attention to puncture location and obtaining adequate haemostasis after sheath removal are the best ways to decrease vascular complications. For example, smaller sheaths (5F) are preferred in patients with significant peripheral vascular disease. Frequent aspiration and discarding of blood from the arterial sheath, followed by gentle flushing, is useful. If an attempted cannulation is unsuccessful but an arterial puncture has been made, the needle should be withdrawn and adequate manual pressure held (about 5 minutes). If a venous puncture has been made inadvertently, the needle should be removed and pressure held (for about 3 minutes). Proceeding directly to arterial puncture without removing the needle and holding pressure increases the chance of arteriovenous fistula formation. Pseudoaneurysm presents as a painful palpable mass and is associated with a low puncture (usually below the femoral head). Ultrasound is an essential part of managing groin complications. If there is a large pseudoaneurysm present, surgery may be required after a trial of ultrasound-guided compression. Percutaneous injection of thrombin into the pseudoaneurysm has proven to be a more effective alternative to compression. Small pseudoaneurysms (< 2 cm) tend to close spontaneously but should be followed by serial ultrasound examinations. AV fistula formation is also associated with a low puncture. Most go undetected, but if the formation is large enough, patients can experience pain and swelling in the lower extremity. An arteriovenous fistula that does not close spontaneously in 2 to 4 weeks may require surgical repair. Very large AV fistula can lead to high-output heart failure. In such cases, a stent graft or vascular surgery may be required.
- Access site bleeding can be significant. If there is a great deal of oozing around the sheath, it can be exchanged for a sheath 1F size larger. Adequate manual pressure is usually sufficient to stop bleeding after sheath removal. It is a typical practice to check the activated clotting time in patients who had been on heparin before the procedure and only proceed with sheath removal if the clotting time is below 160 seconds. Even more concerning is retroperitoneal bleeding. Small women, particularly those with a high puncture (above the upper third of the femoral head) are at greatest risk for retroperitoneal hematoma. Retroperitoneal haematoma should be suspected if a patient complains after a catheterization of severe lower abdominal, back pain, neurologic changes in the leg in which the puncture was made, hypotension, tachycardia, pallor, or a rapidly falling haemoglobin. Obese patients, in particular, can have a major bleed without obvious external signs. Noncontrast CT scan of the abdomen and pelvis can diagnose a retroperitoneal bleed. Patients who have developed a documented retroperitoneal hematoma or are suspected of having this complication are monitored closely in an intensive care unit, often with continuous blood pressure assessment using an arterial line and receive aggressive volume resuscitation with fluids and blood products until self-resolution with reversal of anticoagulation or definite treatment.
- Severe anaphylactoid reactions to contrast dye occur in about 0.1% of cases. Local anaesthetics can also cause problems due to specific allergies to the amide or ester component or to the preservative. A variety of agents are available. Procaine (an ester agent), lidocaine (an amide agent), and bupivacaine (a preservative-free amide agent) are alternative agents. Treatment is discussed above.