Quick Review of Tran-Esophageal Echocardiography

I. General Principles

- **Contraindications to TEE include** esophageal stricture, diverticulum, tumor, and recent esophageal or gastric surgery.

- **The TEE transducer should be inspected** for defects and cracks in the waterproof covering before insertion.

- **The patient's mouth should be examined** for preexisting injuries and loose teeth.

- **The TEE probe may be inserted into an anesthetized, tracheally intubated patient** with or without the use of a laryngoscope by displacing the mandible anteriorly and inserting the probe gently in the midline. Flexing the neck may help in some cases. If blind insertion of the probe is not easy, a laryngoscope can be used to expose the glottis and permit direct passage of the probe posteriorly into the esophagus.

- **Once in the esophagus, the transducer should never be forced through a resistance**. If the probe does not pass smoothly, assistance from an endoscopist should be sought. The tip of the transducer should be allowed to return to the neutral position before advancing or withdrawing the probe, and excessive force should never be applied when moving the transducer in the esophagus or flexing the tip with the control wheels.

- **When examining the heart with TEE, the transducer is first moved into the desired location, and then the probe is manipulated** to obtain the desired image. This is accomplished by watching the image develop as the probe is manipulated, rather than by relying on the depth markers on the probe or the multiplane angle icon.

- **There is no universally agreed upon transesophageal approach for the examination of cardiac structures**. In practice, however, one tends to first examine structures of immediate interest on the basis of clinical indications and transthoracic echo findings. In the awake patient, it is best not to begin examination with the probe placed high up in the oesophagus or in the stomach because this may result in gagging and increased patient discomfort. We often begin examination with the probe in mid-oesophagus and proceed with the examination of structures from a high oesophageal or transgastric position only after the patient has relaxed.

II. Probe manipulation



The 5 main manoeuvres to direct the imaging sector

1. Push to advance, pull to withdraw: UE **(20** cm)→ ME **(30)** → TG **(40)** → Deep TG **(50)**

Push to advance

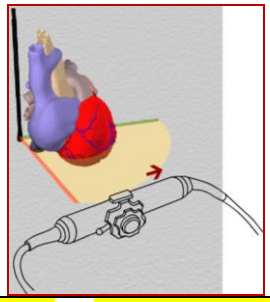

Pull to withdraw (e.g. LV→AV)

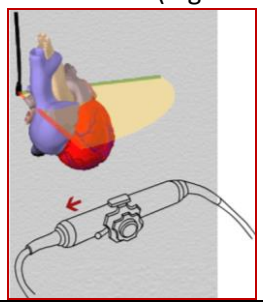

2. Twisting the Probe → turn the scope rightward or leftward

Turn the scope rightward (clockwise) (e.g. LV→AV)

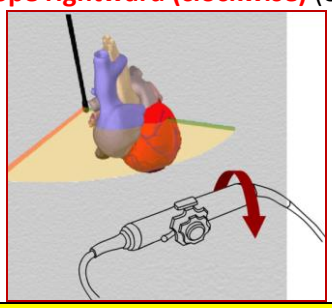

Turn the scope leftward (counter-clockwise)

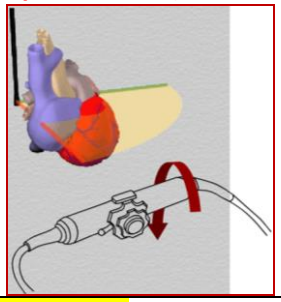

3. Turn the LARGE control WHEEL in the handle → probe tip antiflexion or retroflexion

Antiflexion (e.g. for LAA)

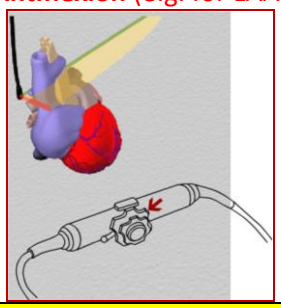

Retroflexion (e.g. for LV)

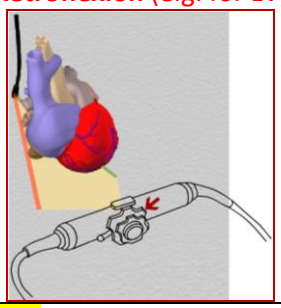

4. Turn the SMALLER control WHEEL → flex the probe tip rightward or leftward (rarely used)

Flex the probe tip rightward

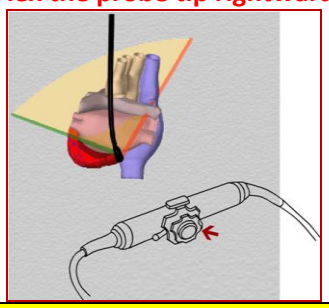

Flex the probe tip leftward

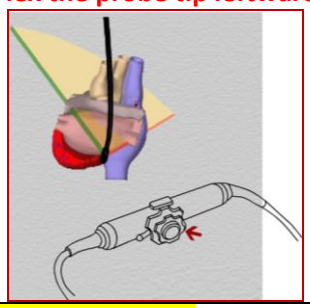

5. Depressing a BUTTON on the handle → rotate the imaging sector through an arc of 180°

Rotate the imaging sector forward toward 180°

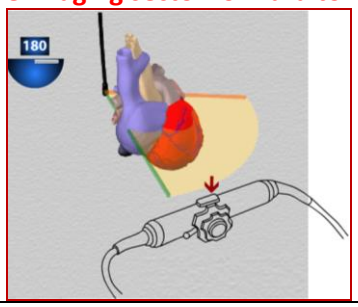

Rotate the imaging sector backward toward 0°

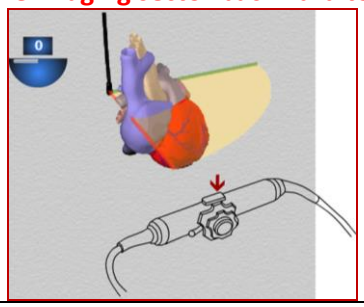

III. Conventional Image Display

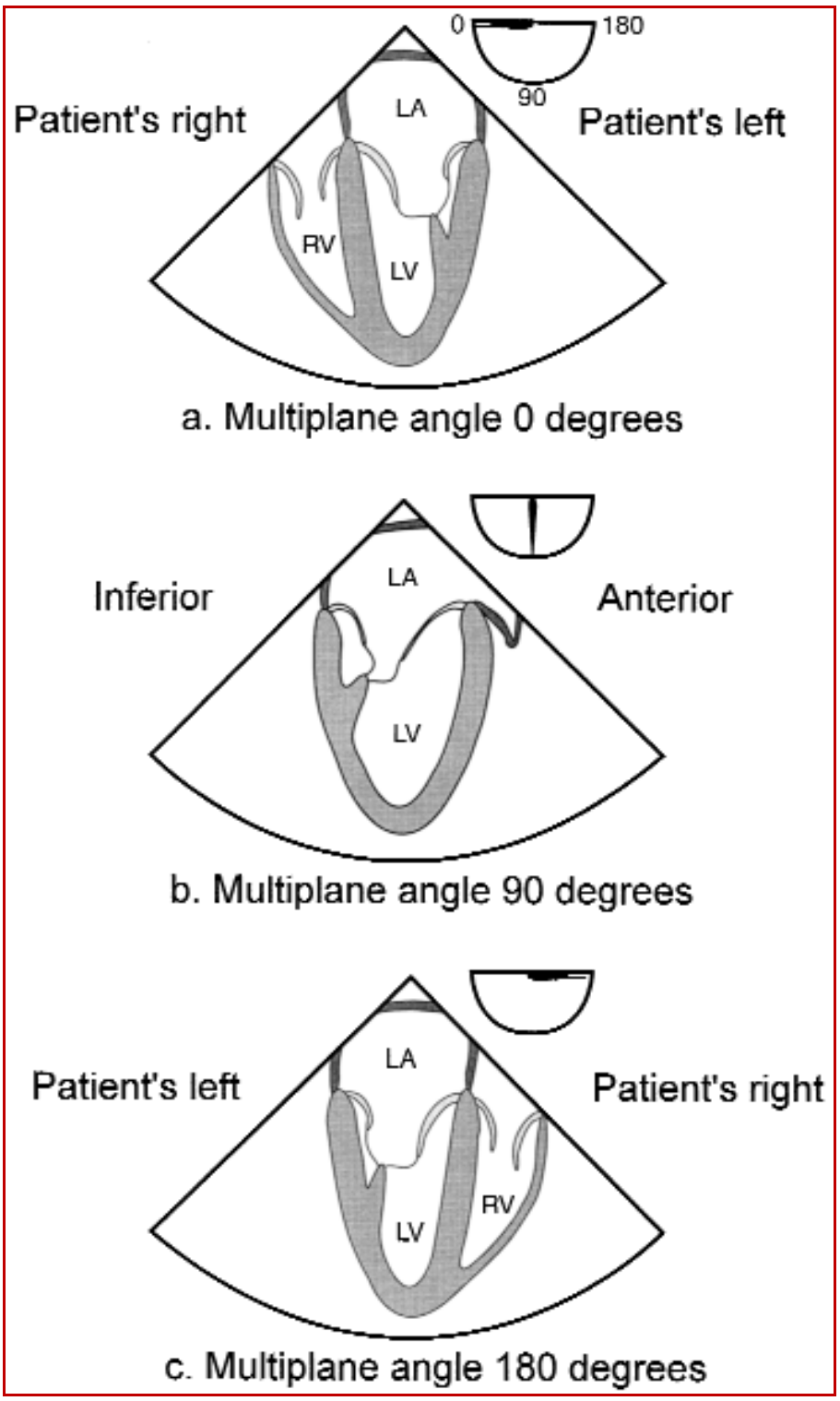

Figure: Conventions of image display followed in the guidelines: transducer location and the near field (vertex) of the image sector are at the top of the display screen and far field at the bottom.

A. At a multiplane angle of **0^0 (the horizontal or transverse plane), with the imaging plane directed anteriorly from the esophagus through the heart, the patient's right side appears in the left of the image display**.
B. Rotating the multiplane angle forward to **90^0 (vertical or longitudinal plane) moves the left side of the display inferiorly**, toward the supine patient's feet.
C. Rotating the multiplane angle to **180^0 degrees places the patient's left side to the left of the display, the mirror image of 0 degrees.**

IV. Anatomic Considerations & Practical Hints

LV orientation

The LV is usually oriented within the patient's chest with its apex somewhat more inferior than the base, so the tip of the probe may require retroflexion to direct the imaging plane through the apex in the ME 4c view.

16 Segments Model of LV in TEE

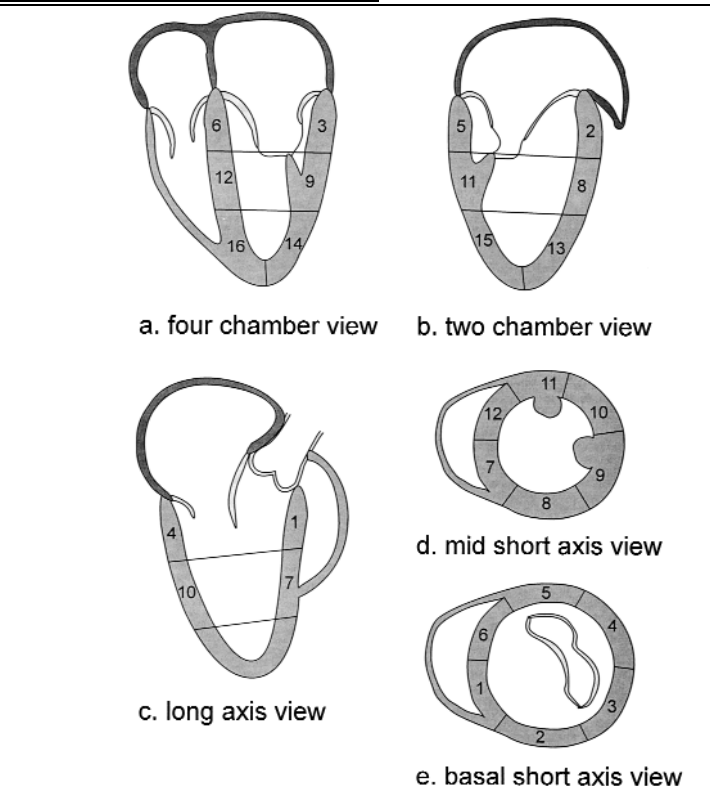

Basal Segments	Mid Segments	Apical Segments
1= Basal Anteroseptal	7= Mid Anteroseptal	13= Apical Anterior
2= Basal Anterior	8= Mid Anterior	14= Apical Lateral
3= Basal Lateral	9= Mid Lateral	15= Apical Inferior
4= Basal Posterior	10= Mid Posterior	16= Apical Septal
5= Basal Inferior	11= Mid Inferior	
6= Basal Septal	12= Mid Septal	

All 16 segments of LV are examined by obtaining five views of the LV, three through the ME window and two through the TG window.

A, ME 4c view shows the three septal and three lateral segments. **B,** ME 2c view shows the three anterior and three inferior segments.

C, ME LAX view shows the two anteroseptal and two posterior segments.

D, TG mid SAX view shows all six segments at the mid level.

E, TG basal SAX view shows all six segments at the basal level.

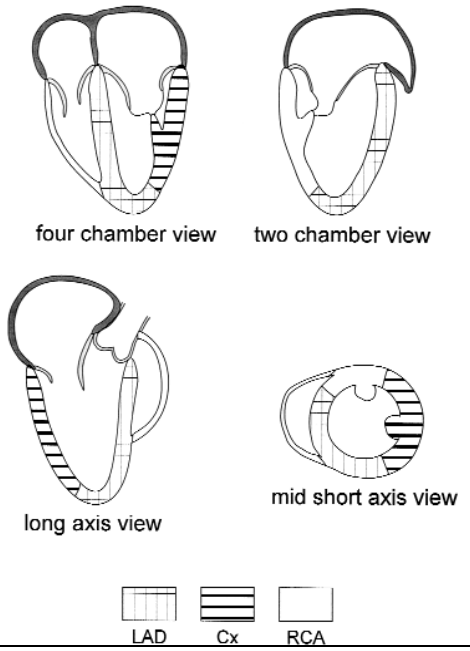

Typical regions of myocardium perfused by each of the major coronary arteries to the left ventricle. Other patterns occur as a result of normal anatomic variations or coronary disease with collateral flow.

Right Ventricle

Formal segmental scheme for the RV free wall has not been established, but the terms basal, apical, anterior, inferior, and RVOT may be used to localize specific regions of the wall.

Mitral Valve Anatomy

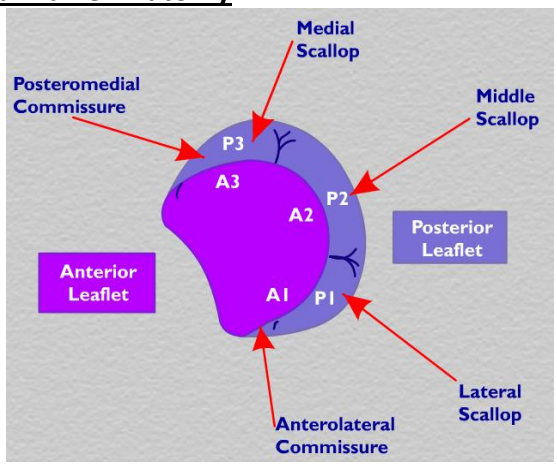

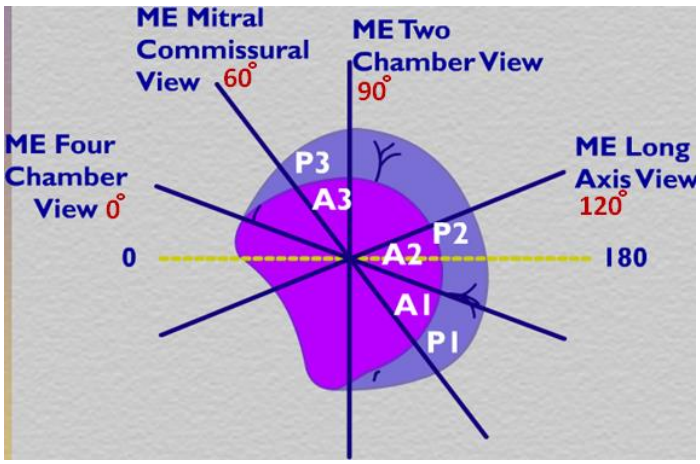

The MV consists of

1. 2 Leaflets: large anterior leaflet and the crescent shaped posterior leaflet. Each leaflet is divided into 3 scallops: (1) lateral, (2) middle, and (3) medial. The two leaflets are joined at the anterolateral and posteromedial commissures, each of which is associated with a corresponding papillary muscle
2. Annulus
3. Chordae tendinae
4. 2 Papillary muscles (AL and PM)

Multiple views are required to interrogate the MV at its entirety:

1. The imaging sector in the ME 4-chamber view interrogates P1 & A1/A3
2. The imaging sector in the ME 2-chamber view interrogates P3 & A3/A1
3. The imaging sector in the ME LAX view interrogates P2 & A2

The Aortic Root

- The aortic root is the anatomic segment between the left ventricle and the ascending aorta. It includes the aortic annulus, the aortic cusps, the aortic sinuses (sinuses of Valsalva), and the sinotubular junction.
- The spaces contained between the aortic annulus and the sinotubular junction are the aortic sinuses or sinuses of Valsalva. There are three cusps and three sinuses: left cusp and sinus, right cusp and sinus, and non-coronary cusp and sinus. The left main coronary artery arises from the left aortic sinus and the right coronary artery from the right aortic sinus.
- The aortic sinuses facilitate closure of the aortic valve by creating eddies currents between the cusps and arterial wall. They also prevent the cusps from occluding the coronary artery orifices during systole, thus guaranteeing myocardial perfusion during the entire cardiac cycle.

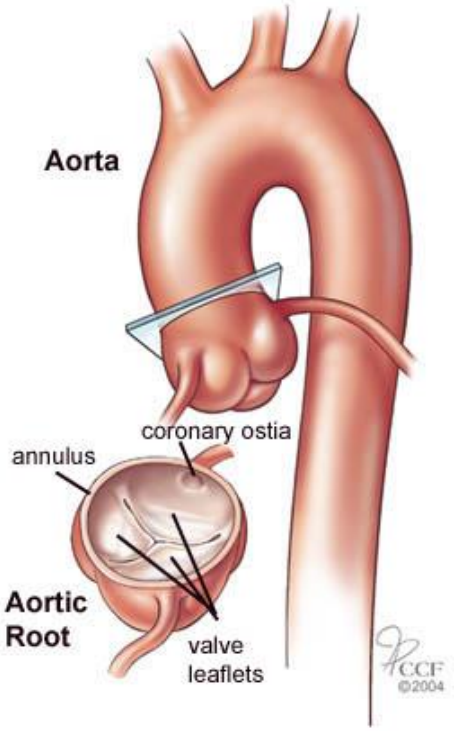

Relationship between descending aorta and esophagus

- **Most of the thoracic aorta can be routinely imaged** with multiplane TEE because it is adjacent to the esophagus as it passes vertically through the mediastinum.

- However, because the air filled trachea is interposed between the esophagus and the **distal ascending aorta and proximal aortic arch**, these regions usually **cannot be visualized** with TEE.

- To visualize the **descending aorta and the distal arch**, turn the probe 180^0 leftward (i.e. **posteriorly).**

- Because of the changing relationship between the esophagus and the descending thoracic aorta, it is **difficult to designate anterior and posterior or right to left** orientations of the descending thoracic aorta in the TEE images. One approach is to describe the location of the defect as a **distance from the origin of the left subclavian** artery and its location on the vessel wall **relative to the position of the esophagus** (e.g. the wall opposite the esophagus). Another approach is to record the **depth of the lesion from the incisors**. The presence of an **adjacent structure**, such as the LA or the base of the LV, may also designate a level within the descending aorta.

- The **mid and distal abdominal aorta** usually are **not seen** because it is difficult to maintain contact between the transducer and the aorta within the stomach.

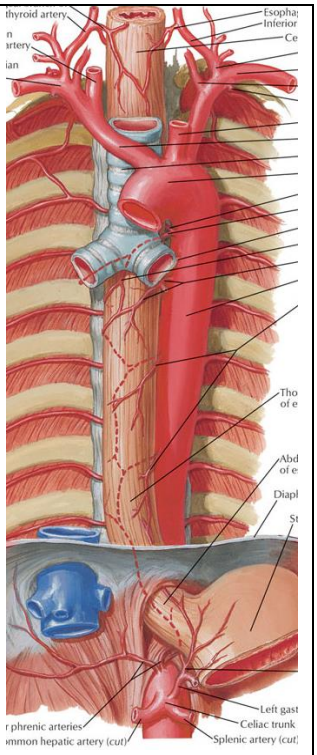

The Coronary Sinus

The coronary sinus is located in the atrioventricular groove along the posterior surface of the heart and empties into the RA (just to the left of the mouth of the IVC) at the most inferior and posterior extent of the atrial septum (adjacent to the septal leaflet of the TV).

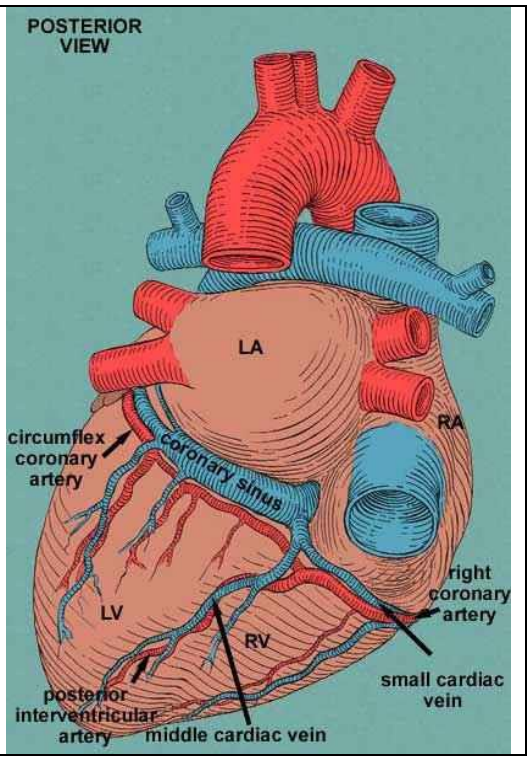

V. TEE Views

Mid oesophageal (ME) views

The mid oesophageal views are analogous to the transthoracic apical views

1) Oesophageal Views, 0 degree

ME 4C → withdraw the prove to ME 5C
→ withdraw the probe + anteflex to maximum ± rotate the angle → LAA→ turn the probe leftward
→ + colour & advancing slightly → LPVs
→ turn the probe rightward (until ISA is horizontal) + colour & advancing slightly → RPVs
advancing ± retroflexion → CS LAX

ME 4C

- **Advance** the probe until you get the 4C view. advance probe to ensure no part of the AV or LVOT is seen (~ 35 cm beyond the patient's incisors)
- **Turn the probe** rightward or leftward to get the 4 chambers in vertical position
- Rotate the **angle** (up to 20°) to maximize the TV diameter.
- Optimize the LV apex by slight **retroflexion** of probe tip
- Adjust the **depth** to include the entire LV (usually 14-16 cm)
- Apply **colour** Doppler, **CW** across the TV and MV, and **PW** across the tips of the opened MV
- Identify the MV leaflets: A3/A2/A1 extending to P2/P1 may be in view at any one time according to the depth of probe insertion, the degree of flexion/extension and also the anatomical lie of the heart which may vary between patients. At **0°**, **A2** (± A3)/**P2** are usually seen. Rotating between **20° and 40°** (± flexion or slight withdrawal of the probe will bring **A1** or A2 (± A3)/**P1** into view.

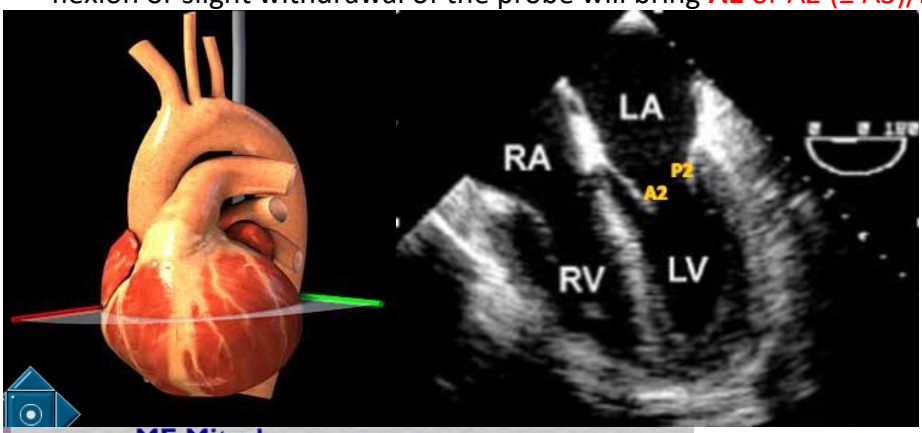

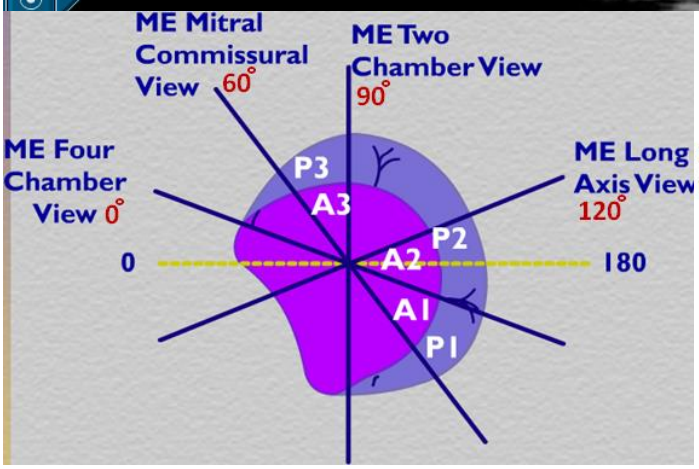

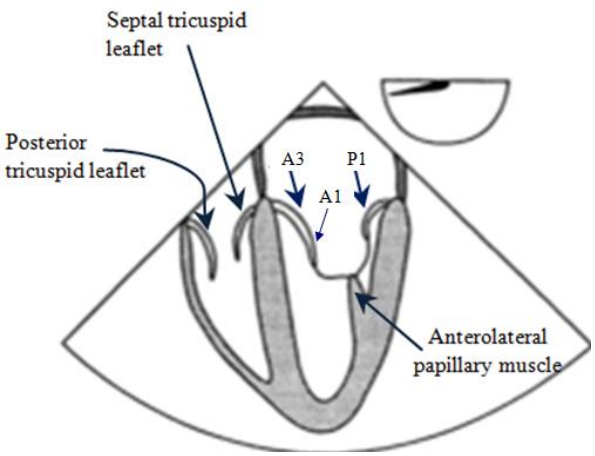

5C view

- From the ME 4C view, **withdraw** the probe slightly to identify the AV & LVOT
- **Turn** the probe rightward or leftward and adjust the **depth** to optimize the view.
- In this view the **NCC** or **LCC** is seen superiorly with the **RCC** seen inferiorly

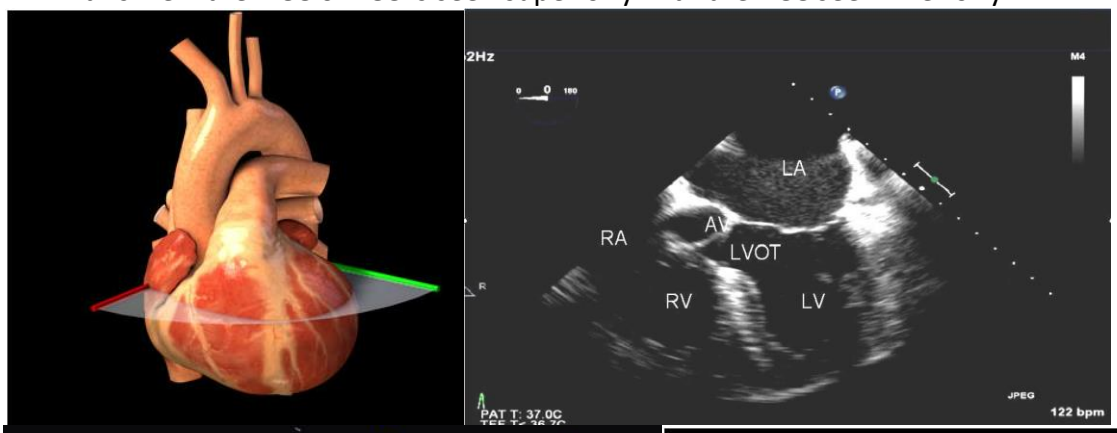

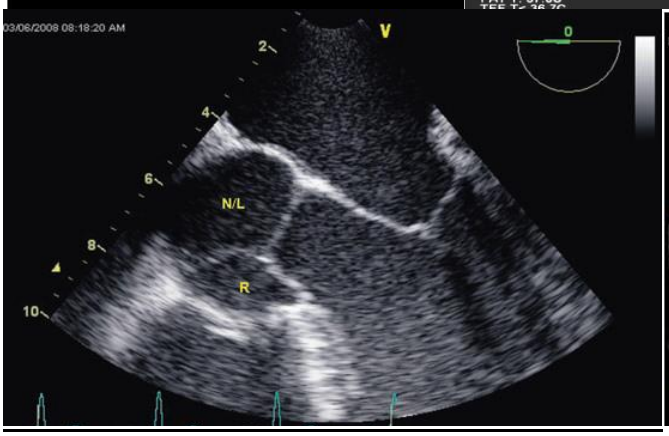

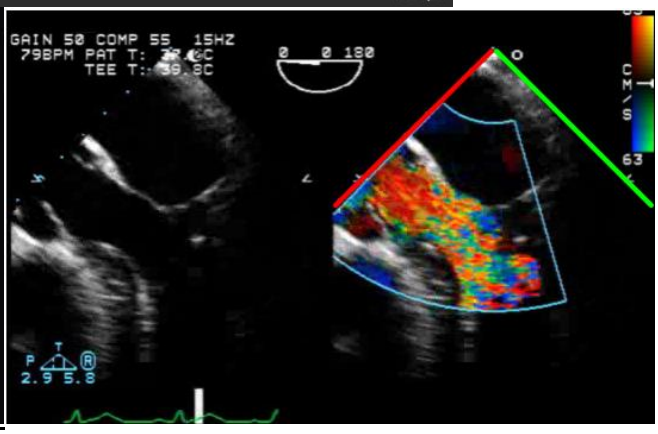

LAA can be seen from the ME 4C by **withdrawing the probe slightly**. The probe is then **maximally ante-flexed** and the image plane **angle rotated** until the appendage is seen.

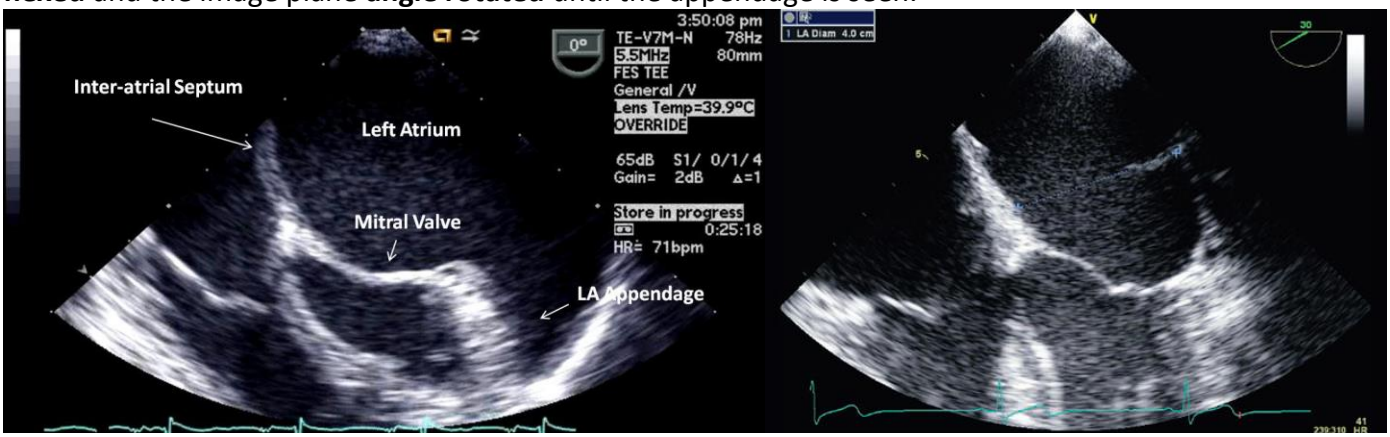

Left Pulmonary Veins can be seen from the ME 4C view by:

- **Withdrawing** the probe slightly.
- **Colour** Doppler is added on the right side of the screen and the **angle** is then rotated until the **LAA** is seen (**between 0° and 60°**)
- The **LUPV** will come into view to the right of the LAA and is identified by its red coded blood flow.
- It is sometimes possible to visualize the **LLPV** by merely **advancing** the probe (**the more vertical flow comes from the LUPV**).
- It is, however, more feasible to image the LLPV by rotating 80–120° (± rotating the probe leftward) until 2 separate inflows are seen converging vertically; in this view the flow to the right of the screen is the LUPV, and the flow to the left of the screen is the LLPV (same view can be obtained starting from the ME 2C → LAA → LUPV → RLLV; see below)

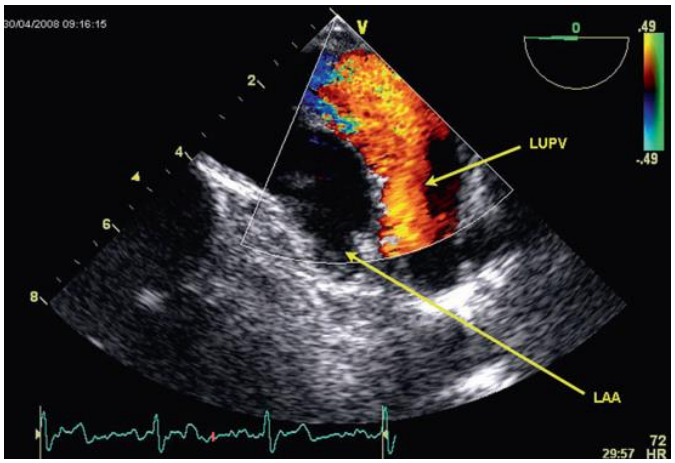

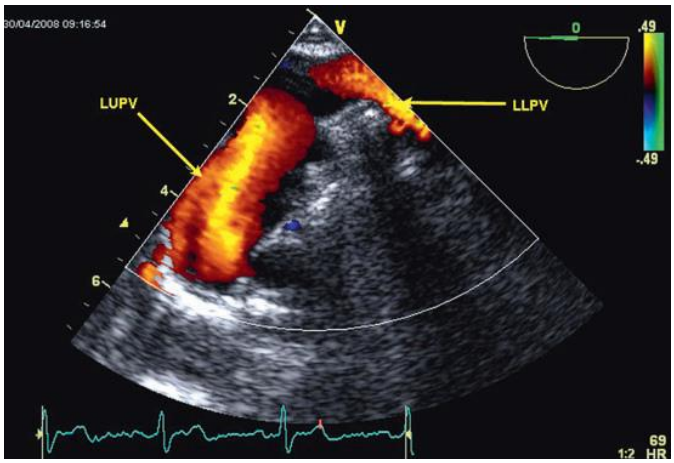

Right Pulmonary Veins can be seen from the ME 4C view by:

- **Rotatin**g the probe to the **right** such that the **IAS is horizontal** and in the centre of the screen.
- **Colour** Doppler is added to the left side of the screen and the probe is **advanced** slowly until 2 distinct pulmonary inflows are seen (**the more vertical flow comes from the RUPV**)

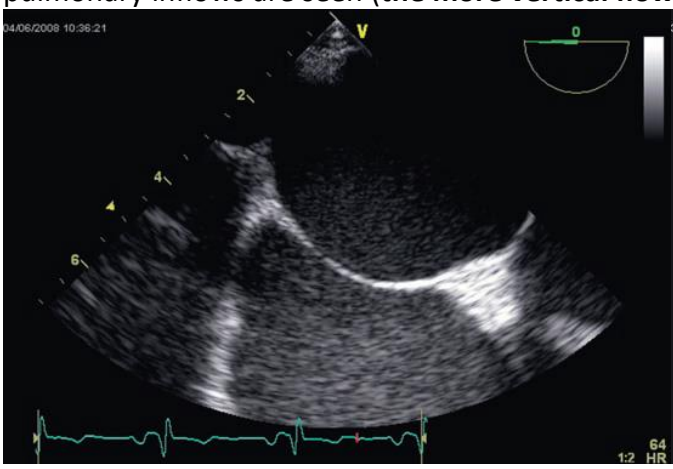

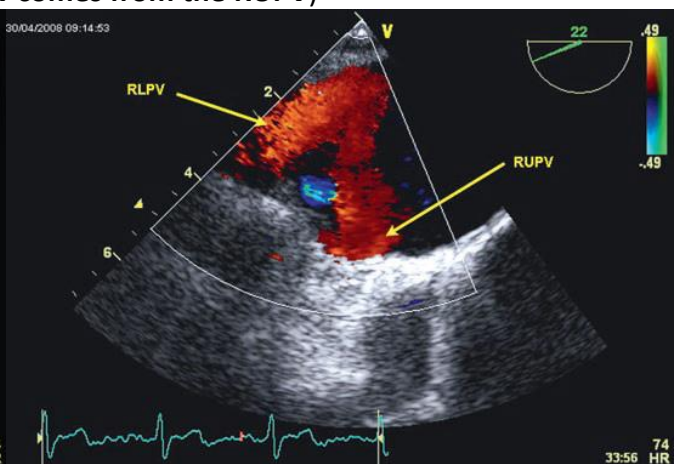

Coronary Sinus LAX can be seen by slightly **advancing** (± **retroflexing**) the probe form the ME 4c view into the **gastro-esophageal junction** (this view is used to verify the placement of coronary sinus catheter. In this view, the presence of a **Eustachian valve** can be confirmed and occasionally a **Thebesian valve** can be seen (at the mouth of the CS).

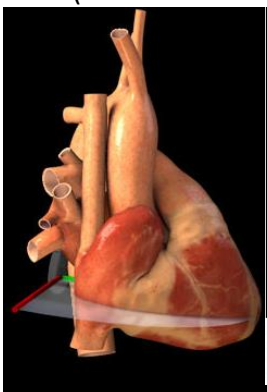

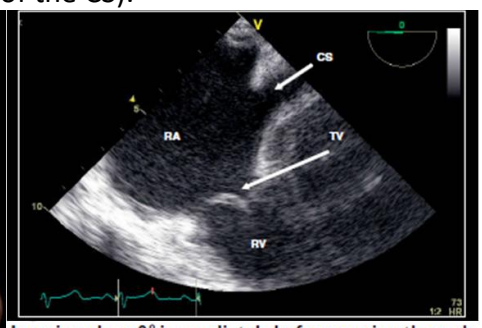

Imaging plane 0° immediately before passing through the gastroesophageal junction, The RA, RV, TV and coronary sinus (CS) are demonstrated.

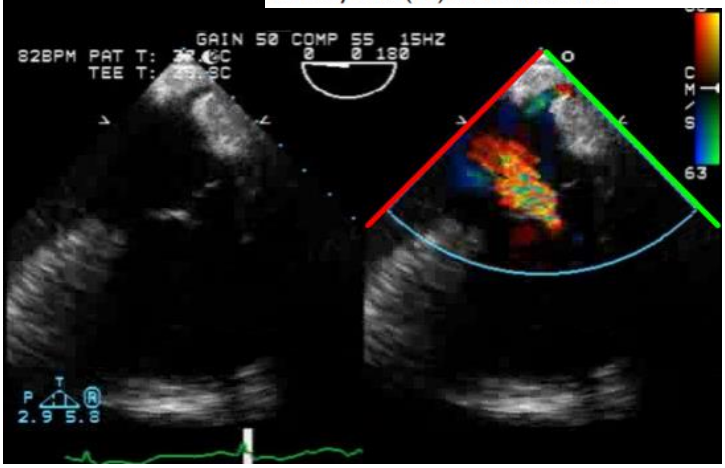

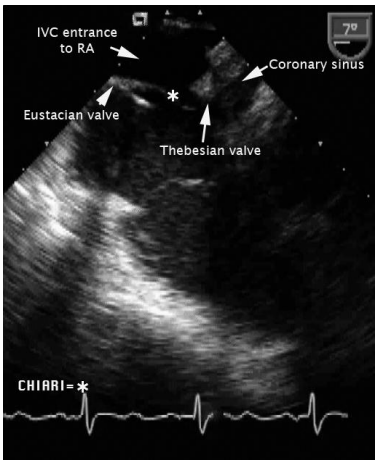

2) Oesophageal Views, 30 degree

AV SAX → prove is withdrawn or anteflexed → **coronary ostia**→ probe is withdrawn and angle is adjusted (0^0 to 40^0) → **Ascending Aorta SAX** + **Pulmonary trunk & bifurcation** → withdraw the probe → **Aortic Arch**

ME AV SAX

- Insert the probe to the ME, find the **ME 4C**
- Withdraw to obtain the **ME 5C** view that includes the LVOT and AV
- Rotate angle to **30-45°**
- **Turn** the probe rightward to centre the AV
- **Anteflex** back to neutral to make the 3 AV cusps symmetric
- Adjust the **depth**
- **Colour** Doppler is applied to detect **AR** and estimate the **size and location of the regurgitant orifice.**

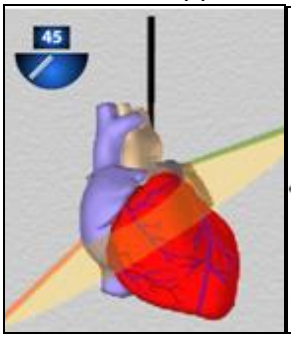

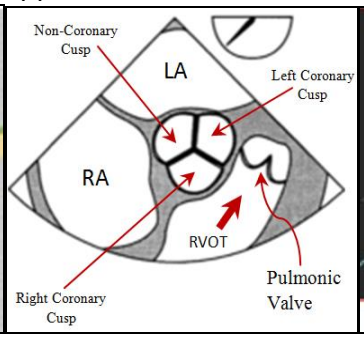

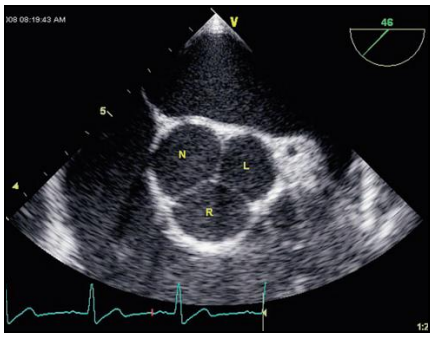

Coronary Ostia

- The probe is **withdrawn or ante-flexed** slightly to move the imaging plane superiorly through the **sinuses of Valsalva;** to bring the **coronary ostia** and then the **sinotubular junction** into view.
- In the AV SAX view, **LMS** and proximal portion of **LAD** and **LCx** branches can be seen. The **RCA** is seen in the SAX view although it is usually better seen in the LAX view.
- Assessment of the ostia and proximal arteries consists of identifying the sinus of Valsalva they originate from (i.e., ensure no anomalous origins), and a qualitative assessment of flow using colour Doppler; the latter allowing identification of high velocity turbulent flow that may suggest a proximal coronary artery stenosis

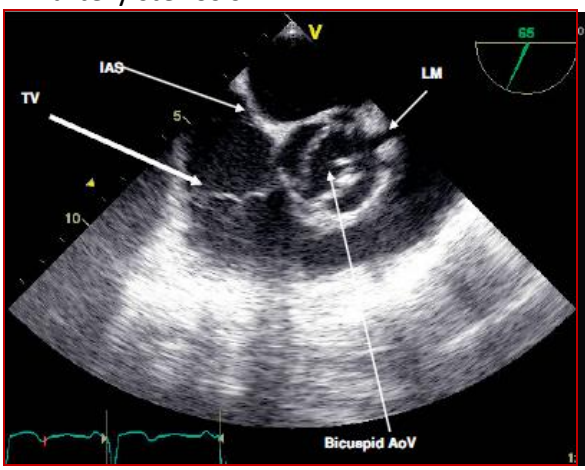

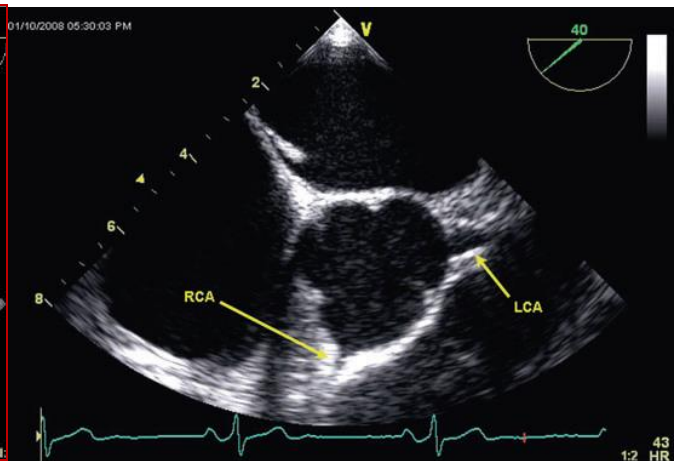

ME Ascending Aorta SAX (+ pulmonary trunk & bifurcation)

- From the ME AV SAX view, **withdraw the probe slightly** until the **right PA** comes into a view (~ **30 cm** from the incisors)
- Adjust the transducer angle **(0^0 to 40^0)** to optimize the circular aorta
- **Withdraw** the probe to examine the **proximal & mid ascending aorta** in short axis

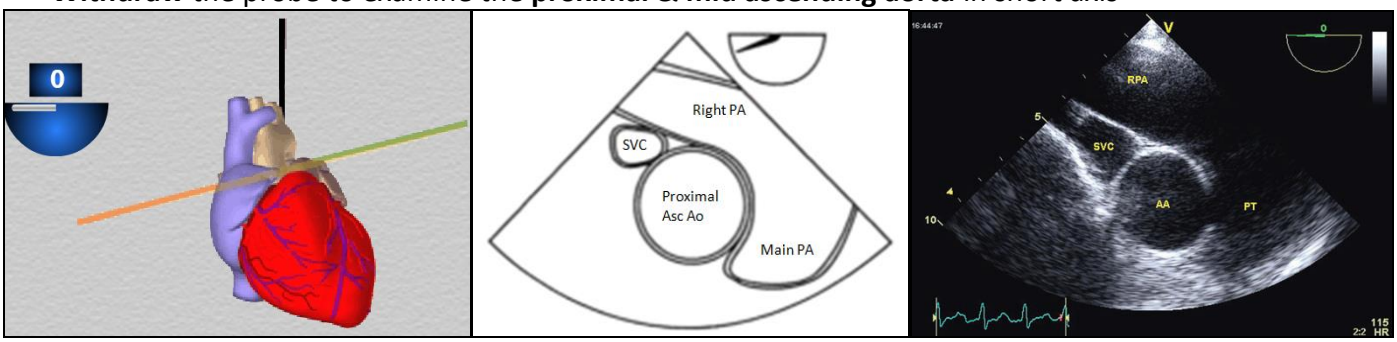

AA: ascending aorta, **SVC**: superior vena cava, **PT**: pulmonary trunk, **RPA**: right pulmonary artery

Aortic Arch

- From the ascending aorta SAX view, **withdraw** the probe to examine the aortic arch.
- While withdrawing the probe, **turn rightward** to keep the aorta in view.
- More commonly this view is obtained starting from the descending aorta SAX view (whilst the probe is turned to face posteriorly) using the same manoeuvre of withdrawing and turning the probe rightward to keep the aorta in view
- Note that the aorta now in the longitudinal appearance not the circular appearance it has in the SAX, since the transverse arch is now imaged in long axis. The proximal arch is to the left with the distal arch to the right.

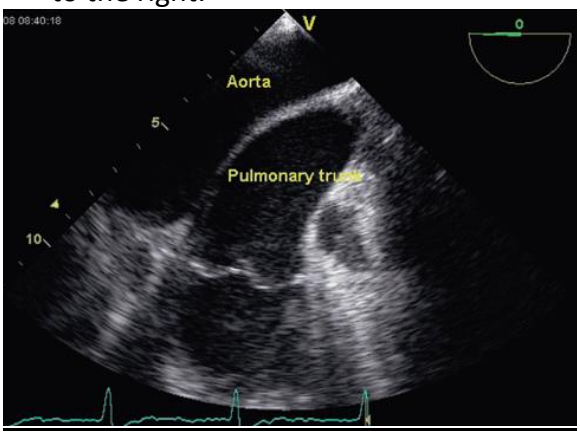

3) Oesophageal Views, 60 degree

ME 4C → turn the probe rightward & rotate the angle to **60⁰** → **RV I-O** → zoom on **PV** (adjust the angle & utilize lateral flexion)
→ keep the probe tip still and rotate the angle to **45- 60⁰** and retroflex → **Mitral commissural**

ME RV inflow-outflowto **the TV in the centre** of the imaging display.

- The image **depth** is adjusted to **include the tricuspid annulus and RV apex.**
- Then rotate the angle to **~ 60⁰** keeping the TV visible until the RVOT opens up and the pulmonic valve and main pulmonary artery appear.
- This view can be obtained form the From the ME AV SAX (30-60°) by rotating the angle to 60-75°
- This view shows the RVOT to the right side of the display and the inferior (diaphragmatic) portion of the RV free wall to the left.
- **Colour** Doppler is applied to detect flow abnormalities of the TV & PV

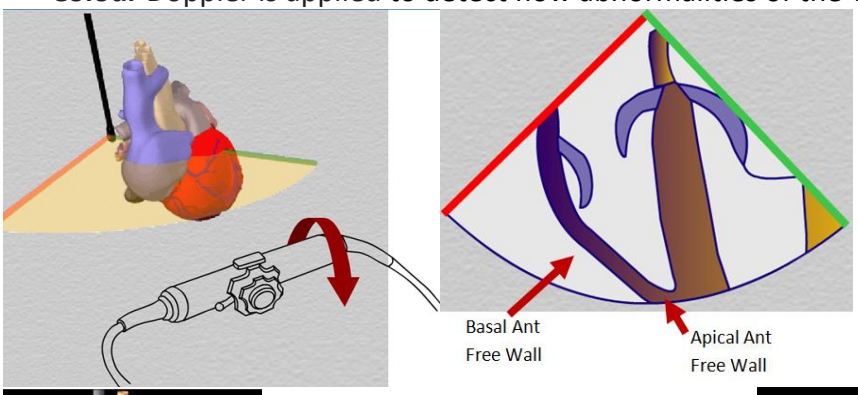

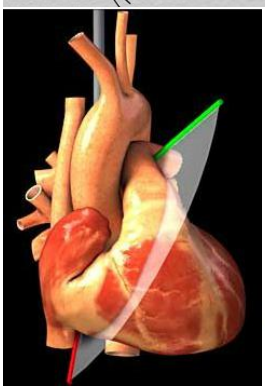

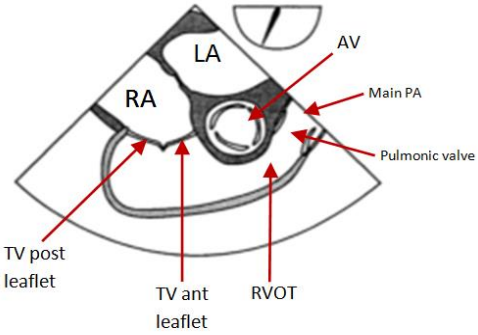

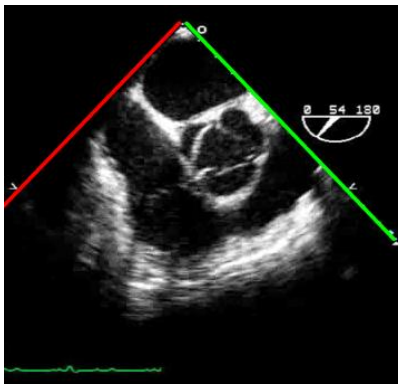

Pulmonic valve

- Zoom on the pulmonic valve and then adjust the angle (usually needs increasing by **10–20° from the standard RV I-O** view) and utilize the **lateral flexion** (usually needs some right lateral flexion)

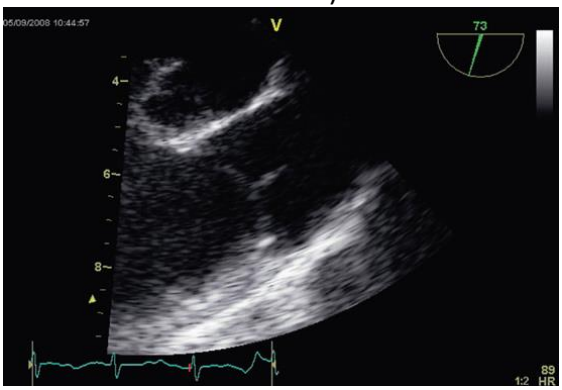

ME mitral commissural view

- From the ME 4c view, keep the probe tip still and the MV in the centre and rotate the **angle** to **45-60°** (RA + RV disappear)
- **Retroflex** slightly for LV apex
- In this view, the imaging sector passes through both the **posteromedial commissure** and the **anterolateral commissure**, and the anterior leaflet is seen in the middle of the LV inflow tract with the posterior leaflet on each side.
- This is an appropriate anatomical plane to measure the annular dimension

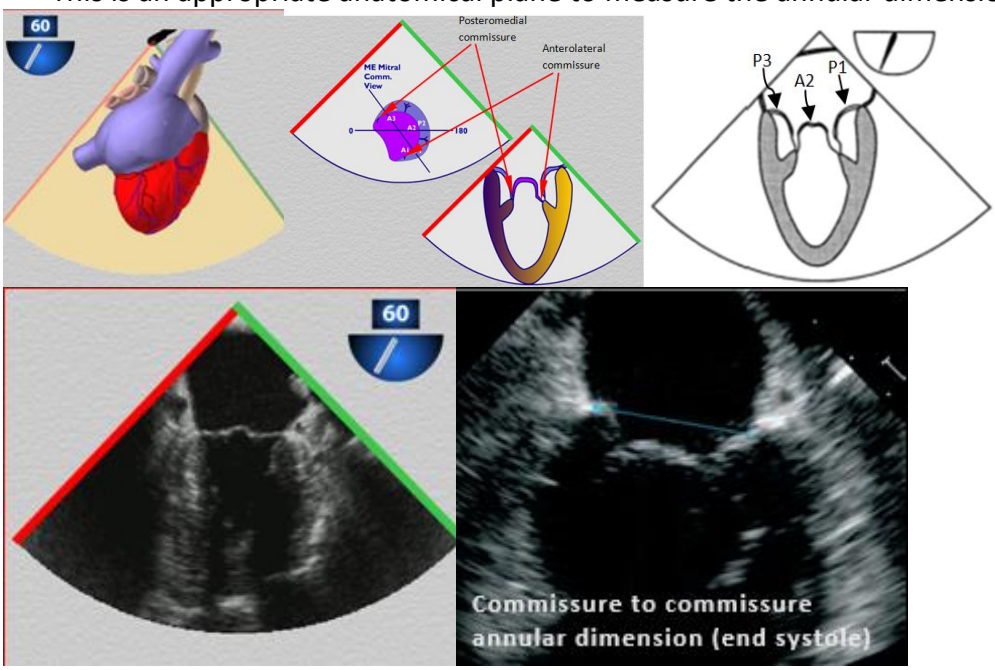

4) Oesophageal Views, 90 degree

ME 2C (+ CS SAX) → withdraw the probe and turn leftward to optimize the **LAA** → advance the probe and turn further leftward to view the **LUPV** → increase the angle (90°-100°) → **LLPV**
turn the probe rightward → **Bicaval (+ RAA)** → increase the angle 100°-120° (modified bicaval) and turn the probe rightward → **TV, CS-LAX, RUPV**

ME 2C

- From the ME 4c view or the mitral commissure view, keep the probe tip still and the MV in the centre, and rotate the angle to ~ **90^0** until the RA and RV disappear & the LAA appears.
- Identify the MV leaflets: **P3** extending to **A1/A2/A3**. Depending on cardiac orientation as well as probe manipulation P2 can be seen
- **Coronary sinus (SAX)**: a short axis image of the coronary sinus is seen to the left of the display in or just superior to the AV groove.
- Identify the "Coumadin Ridge", a prominent muscle ridge between the LAA and the atrial insertion of the LUPV that is often misdiagnosed as thrombus. The lack of mobility and characteristic location, best seen in the ME 2C view, help distinguish it from an abnormal structure.

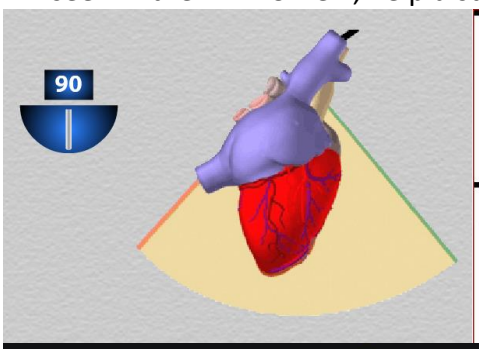

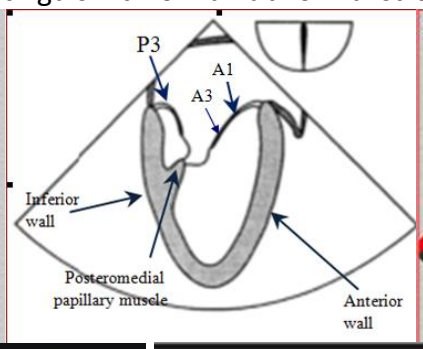

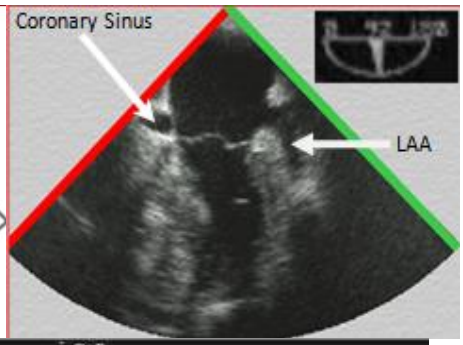

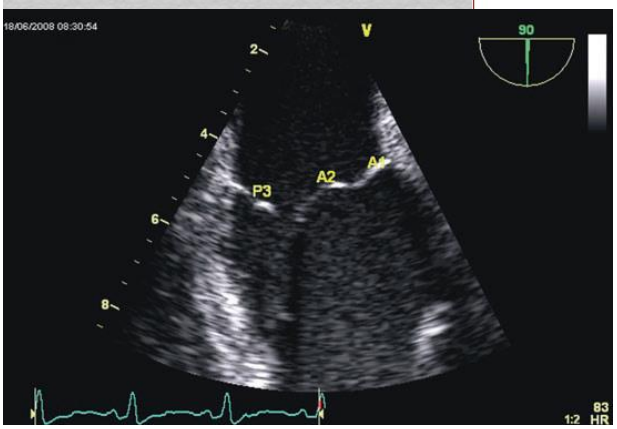

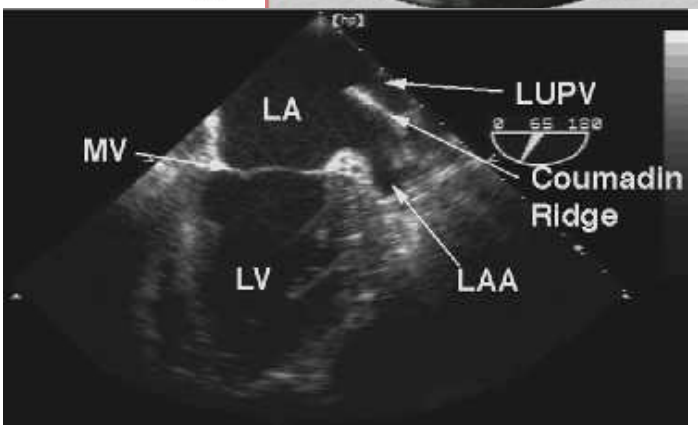

Left atrial appendage (LAA) is optimized by **withdrawing the probe and turning slightly leftward**. The LUPV will come into view to the right of the LAA and is identified by its red coded blood flow

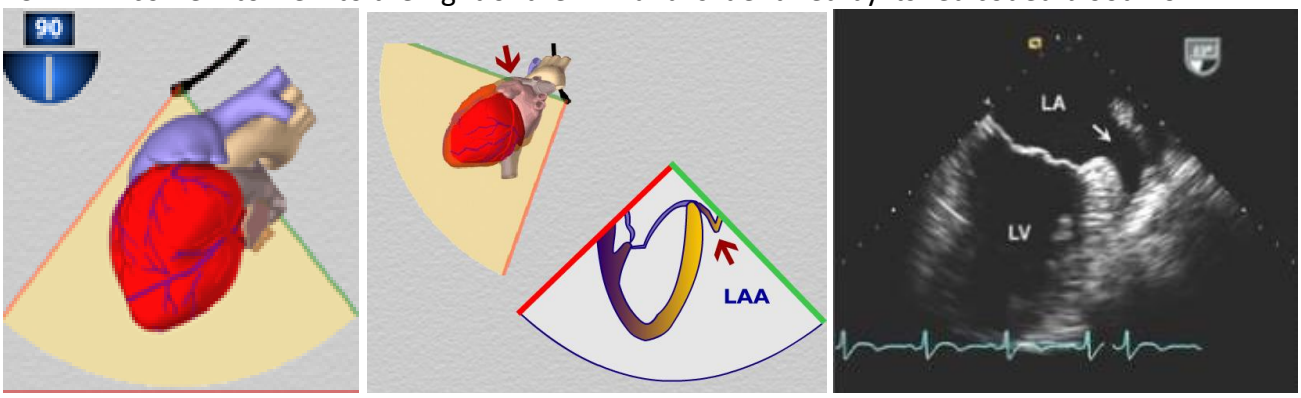

Left upper pulmonary vein (LUPV):

- Identify the **LAA** in the display right
- Use **colour** Doppler
- **Withdraw** the probe slightly and turn slightly **leftward**
- LUPV appears above the LAA

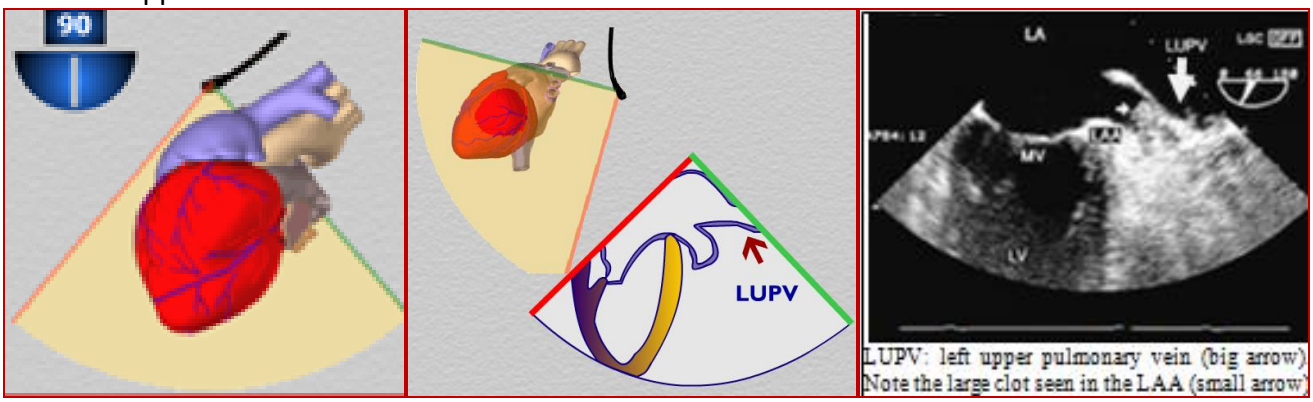

LUPV: left upper pulmonary vein (big arrow)
Note the large clot seen in the LAA (small arrow)

Left lower pulmonary vein (LLPV):

- Centre the **LUPV** on the display with **colour** Doppler
- Use colour Doppler
- **Slowly increase the angle** to 90-100° and identify the bifurcation of the LUPV & LLPV as an **inverted "V"**
- In this view the **flow to the right of the screen is from the upper** and the flow to the left of the screen is from the lower pulmonary vein.

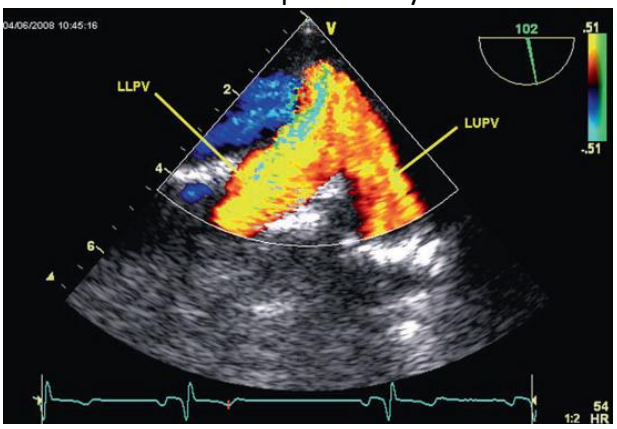

ME Bicaval view

- From the ME 2c view **(angle 90^0)**, **turn the probe rightward** (± rotate the **angle**) until both the **SVC and the IVC** come into view simultaneously. Identify the **ISA** and the body of the **RA**.
- **The right atrial appendage** emanate from the superior, anterior aspect of the RA
- **Eustachian valve** is seen at the junction of the **IVC** and the RA. Occasionally, the Eustachian valve has mobile, serpiginous filaments attached to it, termed the **Chiari network**
- **Crista Terminalis** is seen at the border of the **SVC** / RA

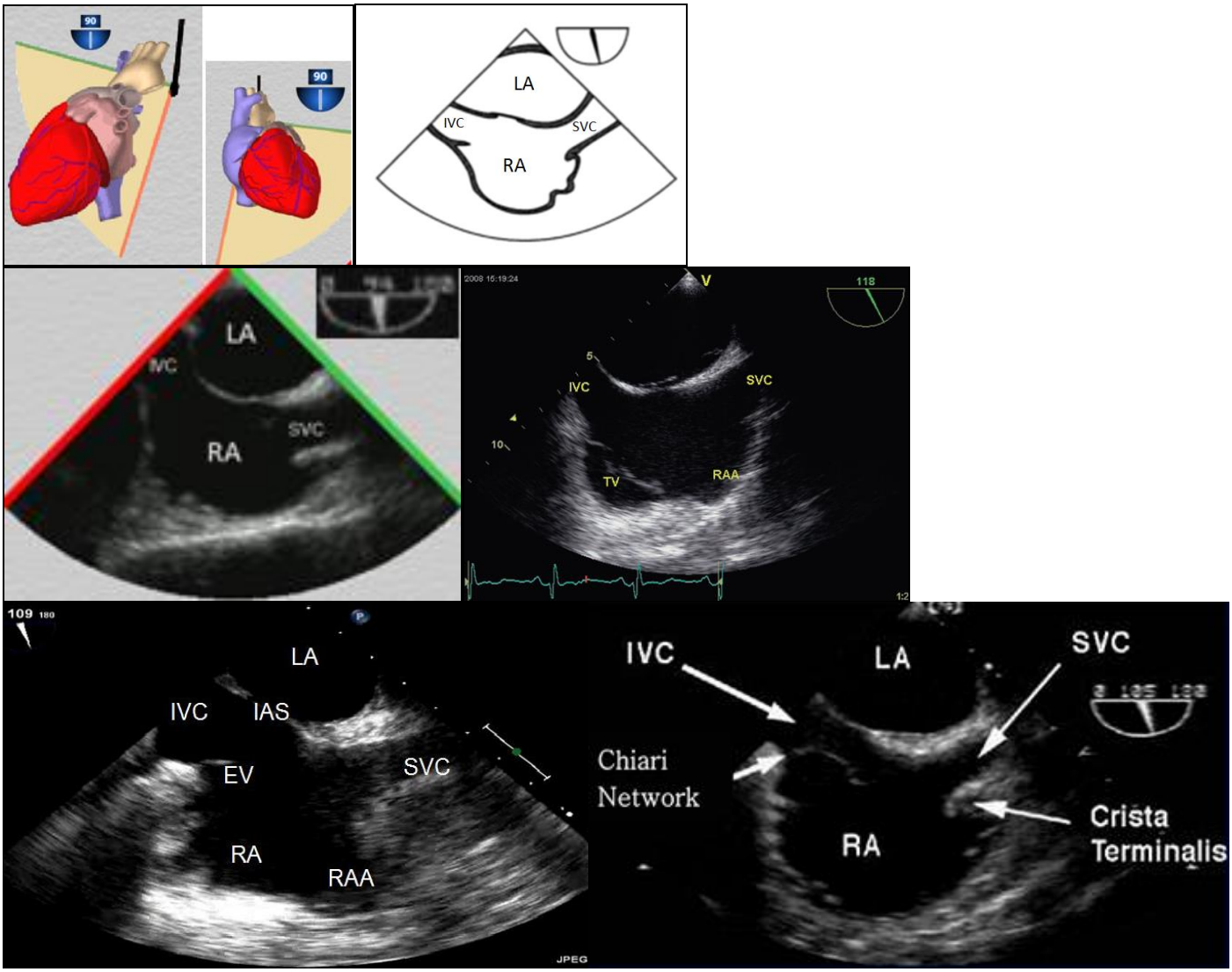

Tricuspid Valve ME View

- From the bicaval view, Increase the angle to **100-120°** (modified bicaval view) and slightly turn the probe **rightward**
- The probe depth and lateral flexion are then adjusted in order to visualize the valve. The anterior leaflet is seen to the right and inferior leaflet is seen to the left of the screen
- This view gives good alignment for spectral Doppler of the TV

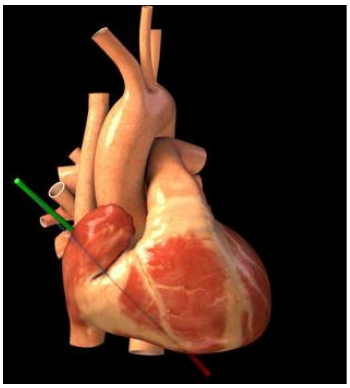
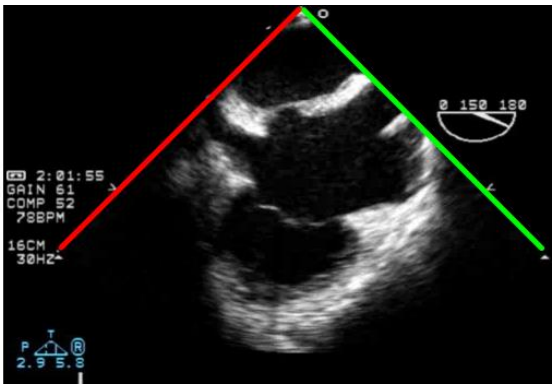

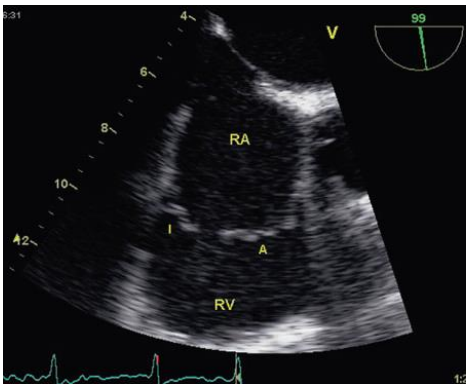

CS LAX View

- From the ME bicaval view (90°), Increase the angle to **100-120°** (modified ME bicaval view)
- Gently turn the probe **rightward**
- Identify the CS in LAX on the display left. In this view the CS should not be confused with the IVC. This view of the CS helps guide the insertion of a coronary sinus catheter.

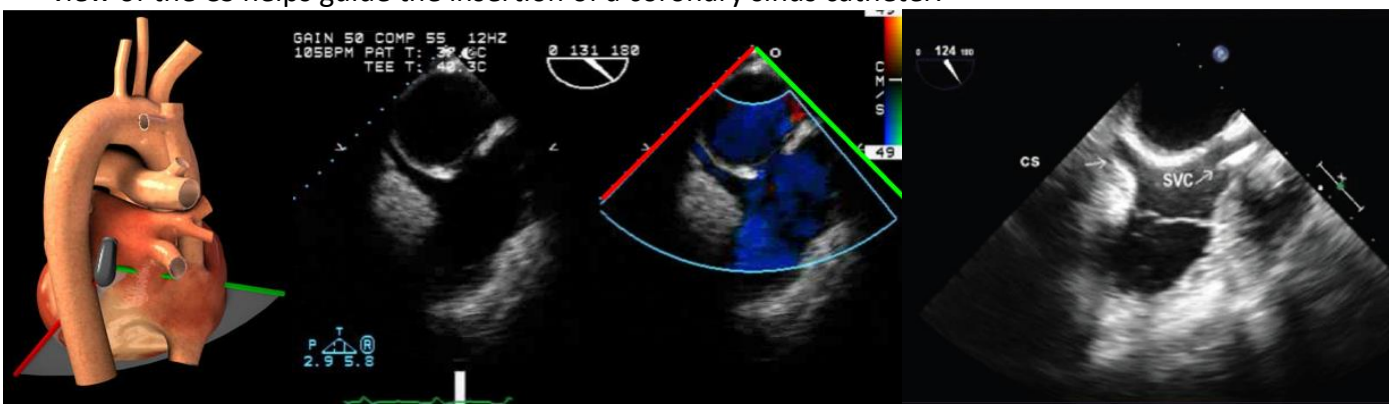

RUPV

- From the bicaval view, put **colour** Doppler in the area of the SVC, increase the angle to **100-120°** (modified bicaval view) and slightly rotate the probe **rightward** to reveal the RUPV entering the LA
- This view of the RUPV is especially useful in patients' with ASD when excluding anomalous pulmonary venous drainage (most commonly the RUPV) and when assessing the distance between the rim of the ASD and the RUPV prior to considering percutaneous closure.

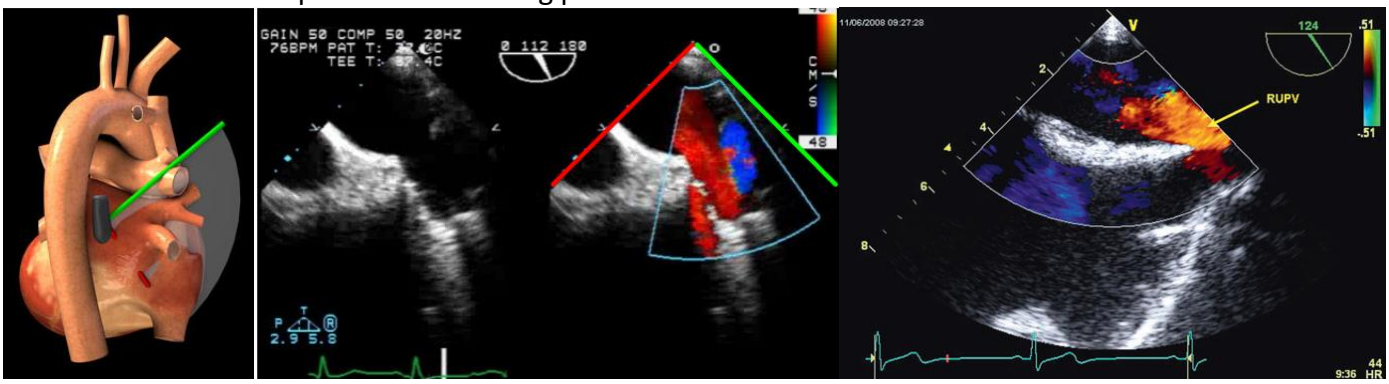

5) Oesophageal Views, 120 degree

Form ME 2C → rotate the angle to 120^0-135^0 to view the **ME LAX**
From ME AV SAX → rotate the angle to 120^0-135^0 to view the **ME AV LAX**
From ME Ascending Aorta SAX→ rotate the angle to 120^0-135^0 to view the **ME Ascending Aorta LAX**

ME LAX

- From the ME 2C , rotate the angle to **~ 120^0-135^0**, until the LVOT, AV, and the proximal ascending aorta come into view.
- Note that all LAX views **should contain a small portion of the RV**.
- Adjust the depth to keep all of LV in view. The entire LV anteroseptal + inferolateral (posterior) walls should be seen. Segments of the anterior (A2) and posterior (P2) are reliably imaged in this view.

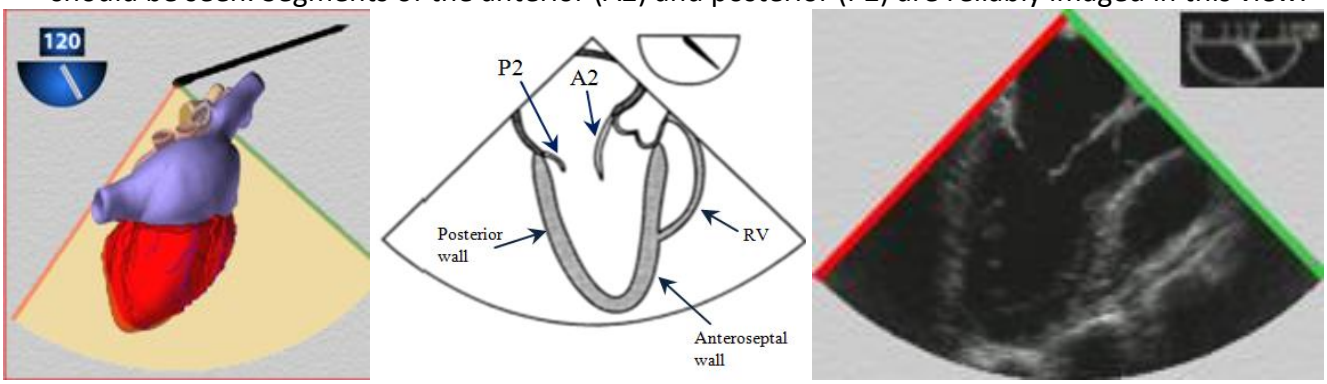

ME AV LAX

- From the ME AV SAX, rotate the angle to **~ 120°-135°** ± turn the probe **leftward**
- Turn the probe rightward or leftward to **align the LVOT, AV & ascending aorta** (to maximize their diameters), and make the **sinuses of Valsalva symmetric** (to optimize the aortic annulus)
- The cusp of the AV that appears anteriorly (toward the **bottom of the display**) is always the **right coronary cusp**, but the cusp that appears posteriorly may be the left or the non-coronary cusp
- The diameter of the **AV annulus is measured during systole** at the points of attachment of the aortic valve cusps to the annulus
- The RCA is seen in the SAX view although it is usually better seen in the LAX view

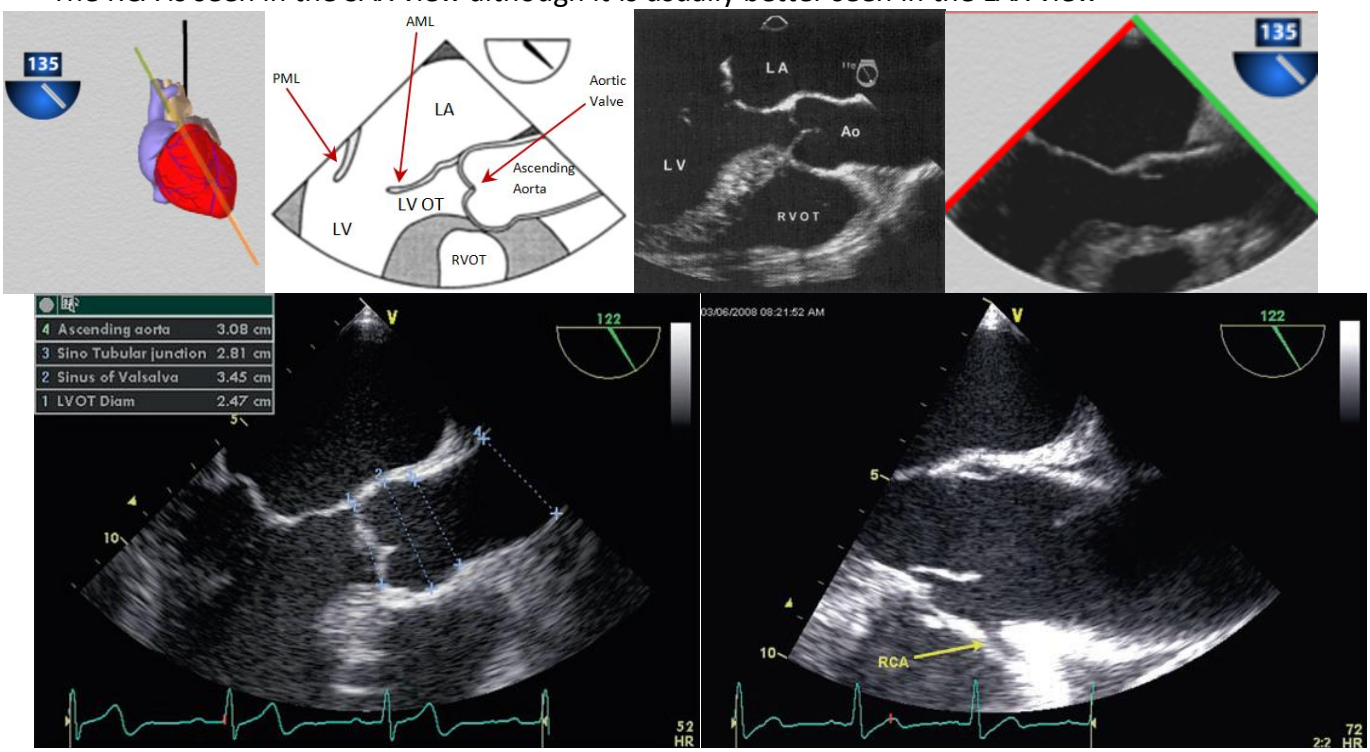

ME Ascending Aorta LAX

- Having assessed the aortic root in the ME AV LAX the probe is withdrawn slightly to bring the **right PA** in view, and the angle decreased to **~ 90^0** to make the aortic wall symmetric
- The same view can be obtained form the ME Ascending aorta SAX , by rotating the angle **~ 90^0.** The aorta now appears tubular rather than circular.
- Turn the probe rightward or leftward to optimize the view so that the walls are parallel and diameter is maximized.
- Various portions of the **proximal & mid Ascending aorta** are visualized by **advancing & withdrawing** the probe.
- Maintaining the probe depth the image plane angle is rotated between 0° and 40° to produce the ascending aorta SAX view

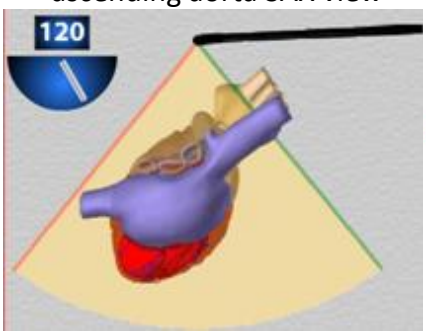

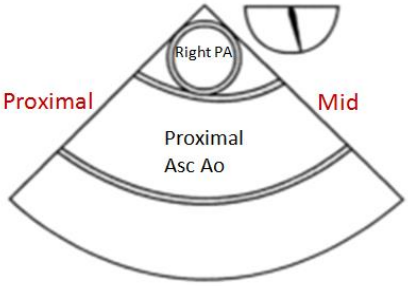

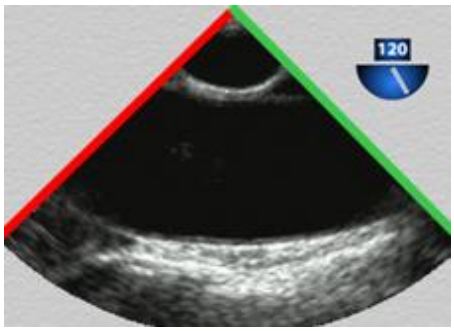

Mid esophageal LV views

- With the imaging plane properly oriented through the center of the mitral annulus and the LV apex, both the **entire LV** and the **entire MV** can be examined, without moving the probe, by simply rotating forward **from 0 to 180 degrees**.

Transgastric (TG) views

The TG SAX and LAX views are analogous to the TTE PSAX and PLAX views.
The TG 2C view looks at the same walls as the TTE apical 2C view, but is interrogating radial as opposed to longitudinal contractility

Gastric views 0 degree:
Home view: LV SAX
Additional views: LV stacks, mitral base

11. TG mid SAX

- Position the transducer **angle at 0°** then **advance the probe** into the stomach (approximately **45 cm** beyond the patient's incisors)
- **Anteflex** the probe tip, until short axis view of the LV appears.
- The probe is then turned rightward or leftward as needed to **center the LV in the display**
- The transducer angle is rotated **between 0^0 and 20^0,** to produce as circular and symmetrical LV cavity as possible.
- The **image depth** is adjusted to include the entire LV, usually **12 cm**.
- This view shows the six mid level segments of the LV and has the advantage of simultaneously showing portions of the LV supplied by all **3 coronary arteries**.
- It is used for assessing **LV dimensions** and calculation of EF%.

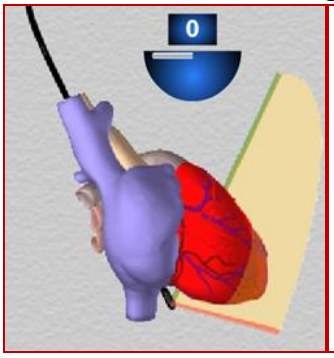

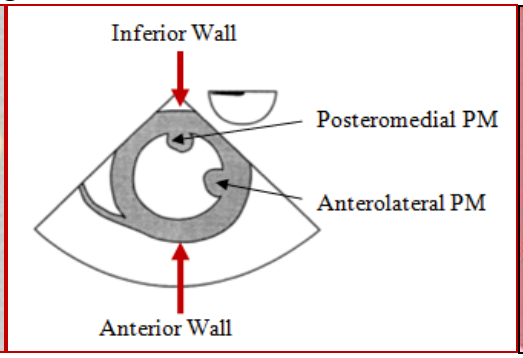

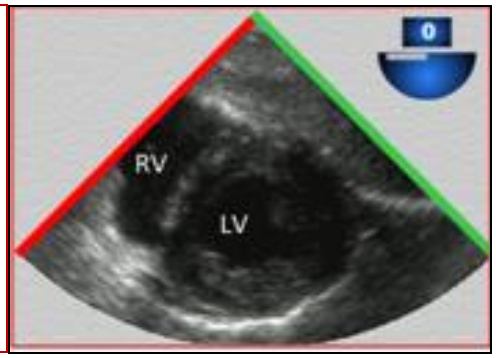

---

12. TG RV inflow

- From the TG mid SAX view; **turn the probe rightward to position the RV in the centre** of the imaging display**.**
- Then rotate the angle to **~ 120°** to develop the trans-gastric RV long axis
- This view also usually provides the best images of the **tricuspid chordae tendinae** because they are perpendicular to the ultrasound beam.
- **Colour Flow Doppler** is applied to assess for TR.

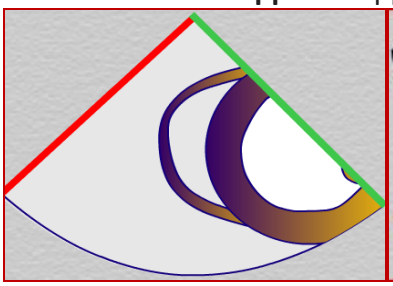
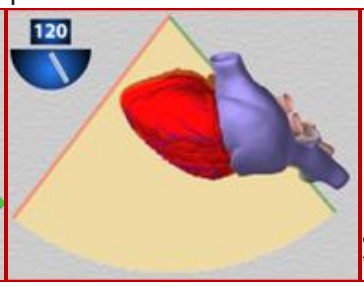

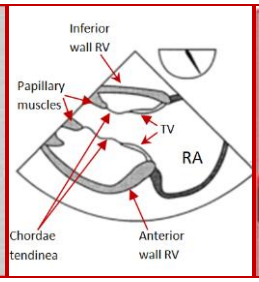

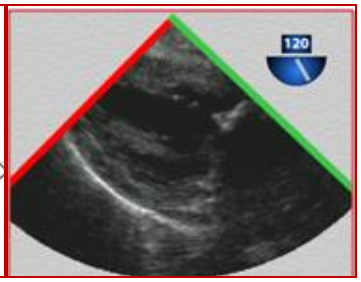

---

13. TG Basal SAX

- From the TG mid SAX view **(angle 0°), slightly withdraw and further anteflex the probe until the MV appears.**
- **Colour Flow Doppler** is applied to assess for MR.
- This view is very useful for determining which portion of the mitral leaflet is abnormal or has abnormal flow.
- This view shows all six basal segments of the LV
- Another approach to develop the **CS LAX view** is to **withdraw the probe from the TG basal SAX** view until the coronary sinus appears in long axis.

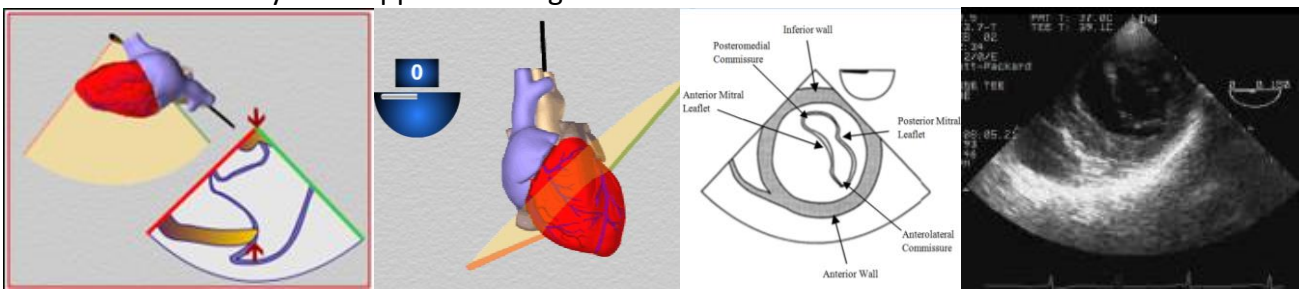

N.B:

Another approach to develop both TG mid SAX and TG basal SAX views is to **start with the TG 2c view**, which shows the LV in long axis, **advance or withdraw** the probe until the desired level is reached (either mid or basal segment), **then rotate the angle back toward 0°** to obtain the SAX view (mid SAX or basal SAX).

---

14. TG 2c

- From the TG mid/basal SAX view, rotate the **angle to 90°.**
- **The probe is turned leftward or rightward** as needed to maximize the length of the LV chamber in the image.
- **Colour Flow Doppler** is applied to assess for MR.
- This view is especially useful for examining the chordae tendinae, which are perpendicular to the ultrasound beam in this view.
- This view shows the basal and mid segments of the inferior and anterior walls, but usually not the apex.

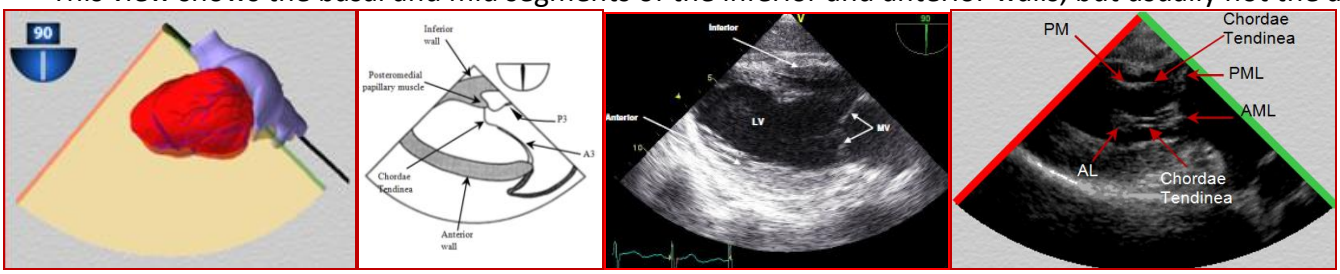

---

15. TG LAX

- From the TG 2c view, rotate the **angle to 120°**.
- **Anteflex** the probe tip (± **turn the probe slightly rightward**) to bring the LVOT, AV, & proximal ascending aorta into view

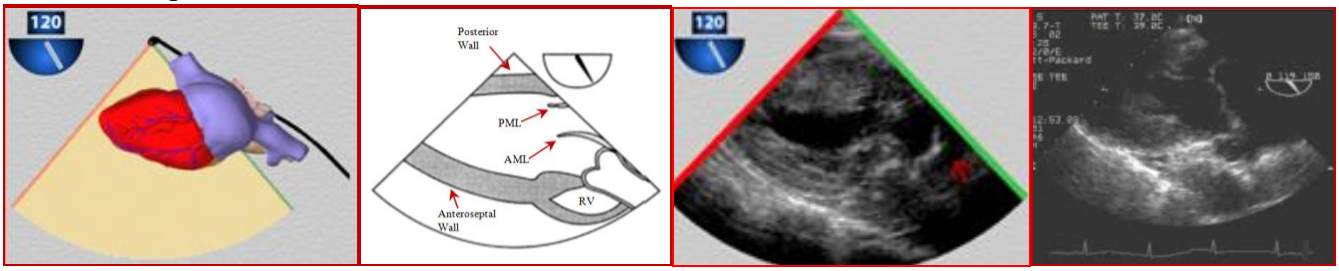

---

16. Deep TG LAX

- From the TG LAX view, **advance the probe further** into the stomach (approximately **50 cm** beyond the patient's incisors).
- Rotate the **angle back to 0°**
- **Anteflex** the tip to approximate the transducer with the LV apex
- Detailed assessment of valve anatomy is difficult in this view because the LVOT and AV are so far from the transducer, but Doppler quantification of flow velocities through these structures is usually possible.

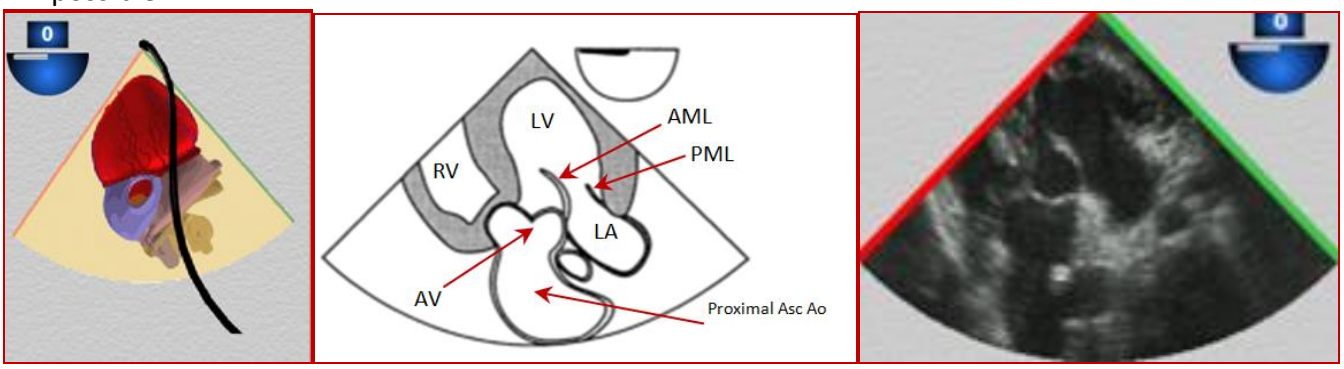

N.B:

- The primary purpose of the two transgastric views of the AV (TG LAX & deep TG LAX) is to direct a **Doppler beam parallel to flow through the AV**, which is not possible from the mid esophageal window.
- Blood flow velocity in the LVOT is measured by positioning the PWD sample volume in the center of the LVOT just proximal to the AV.
- Flow velocity through the AV is measured by directing the CWD beam through the LVOT and across the valve cusps.
- CFD imaging of the LVOT and AV is useful in directing the Doppler beam through the area of maximum flow when making these velocity measurements.

Upper Oesophageal (UE) Views

This part of aortic imaging is often deferred until the end of the study. Having completed all other aspects of the TEE study the image plane angle is set to zero and the probe is manually rotated through 180° to face posteriorly in the ME. The descending aorta is thus imaged in SAX (Fig. 5.11). Maintain the probe position and rotating the image plane angle to 80–120° the descending aorta is seen in long axis (Fig. 5.12). The image plane is then returned to zero degrees and the probe is gradually withdrawn in order to assess the proximal part of the thoracic descending aorta and the aortic arch. In order to maintain the aorta in the centre of the image sector, it is necessary to rotate the probe to the right (anteriorly) as the probe is withdrawn (the aorta and oesophagus twisting around each other within the thoracic cavity; the ascending aorta/aortic arch lying anterior to the oesophagus and the descending aorta lying posterior to it). The arch is first seen in a long axis projection (Fig. 5.13), and then by rotating to 80–120° (although sometimes at lesser angles), in the SAX projection (Fig. 5.14). These arch views are very useful especially in assessing stroke patients (looking for arch atheroma), but are often not well tolerated as the probe at this depth within the oesophagus tends to induce a significant gag reflex in the majority of patients.

Descending aortic SAX

- From the ME 4c view **(angle 0^0), turn the probe 180^0 leftward** until the circular descending aorta cross section appears in the center of the near field (vertex) of the display.
- The image **depth** is decreased to **6 to 8 cm** to increase the size of the aorta in the display and the **focusing depth moved to the near field** to optimize image quality.
- **Advance & withdraw** the transducer to interrogate the **descending thoracic aorta**

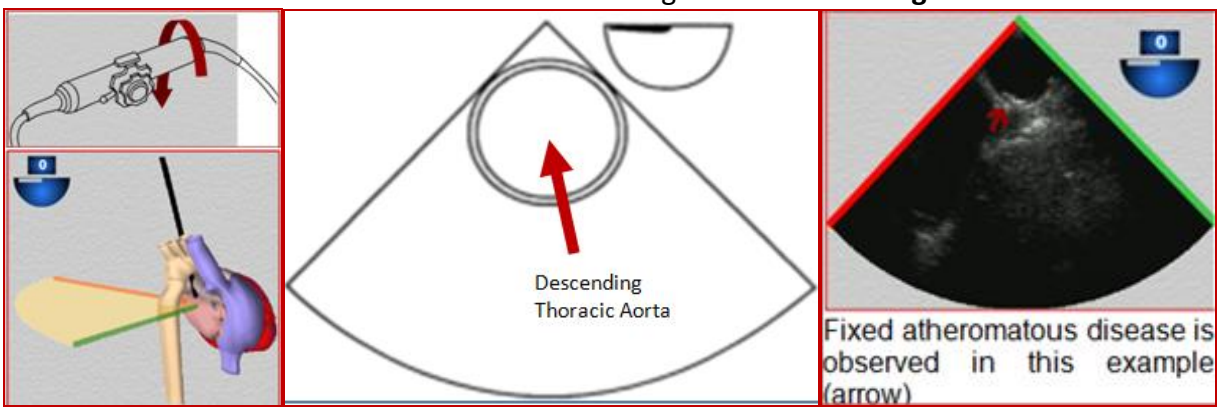

18. Descending aortic LAX

- From the Desc aortic SAX, rotate the angle to **~ 90°** to achieve the longitudinal appearance.
- Examine the entire **descending thoracic and upper abdominal aorta** by **advancing & withdrawing** the probe

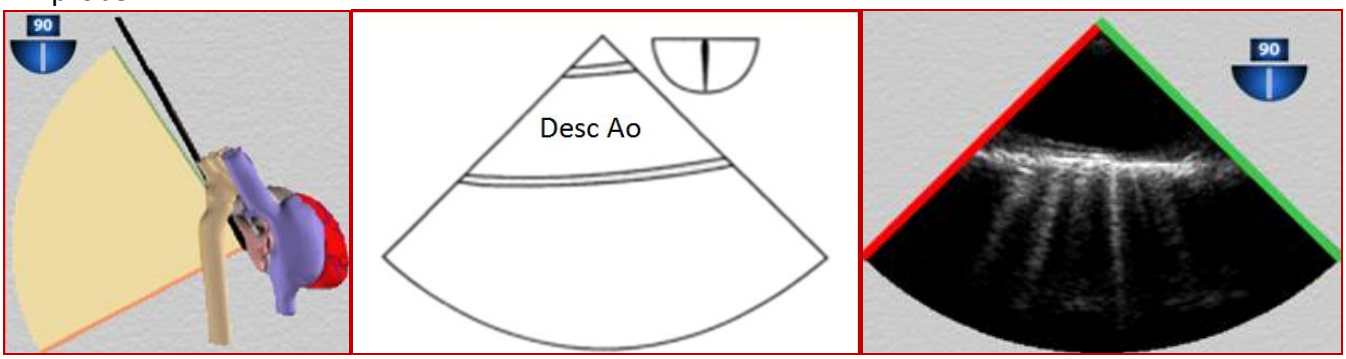

N.B:

- The esophagus is located posterior to the descending aorta at the level of the distal arch and then winds around within the thorax until it is anterior to the descending aorta at the level of diaphragm
- Because of the changing relationship between the esophagus and the descending thoracic aorta, as the probe is advanced within the esophagus starting from the distal arch, it is turned leftward (posteriorly) to keep the descending aorta in view.

19. UE aortic arch LAX

- From the descending Aortic SAX view **(angle 0^0), withdraw the probe** while maintaining an image of the descending thoracic aorta until the upper esophageal window is reached, at approximately **25 cm** from the incisors.
- Because the **mid aortic arch** lies anterior to the esophagus, as the tip of the probe is **withdrawn farther**, it needs to be **turned rightward (anterior)** to keep the vessel in view.
- Note that the aorta now in the longitudinal appearance not the circular appearance it has in the SAX, since the transverse arch is now imaged in long axis.
- The proximal arch is to the left of the display and the distal arch to the right.
- In some individuals, withdrawing the transducer farther from the upper esophageal aortic arch long axis view can image the proximal **left subclavian** artery and **left carotid** artery. The right brachiocephalic artery is more difficult to image because of the interposition of the air filled trachea. As the transducer is **withdrawn**, it is **turned leftward** to **follow the left subclavian** artery distally. The **left internal jugular** vein lies anterior to and to the left of the common carotid artery and sometimes is seen. The **left brachiocephalic** (left innominate) vein is also often seen anterior to the arch

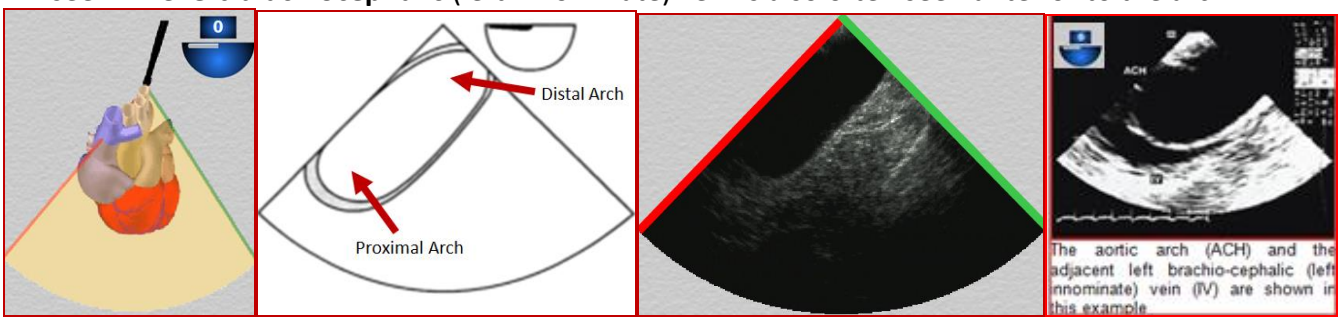

20. UE aortic arch SAX

- From the UE aortic arch LAX, rotate the angle **to 90°**
- **Turn the probe rightward** to move the imaging plane **proximally through the arch** and **leftward** to move **distally**.
- The **origin of the great vessels** often is identified at the superior aspect of the arch to the right of the display.
- **Retroflexing** the probe will often improve the view of the **PV**. This view usually allows the Doppler beam to be aligned parallel to flow through the PV and main PA. **CFD** and **CW Doppler** can be applied assess flow through PV and main PA.

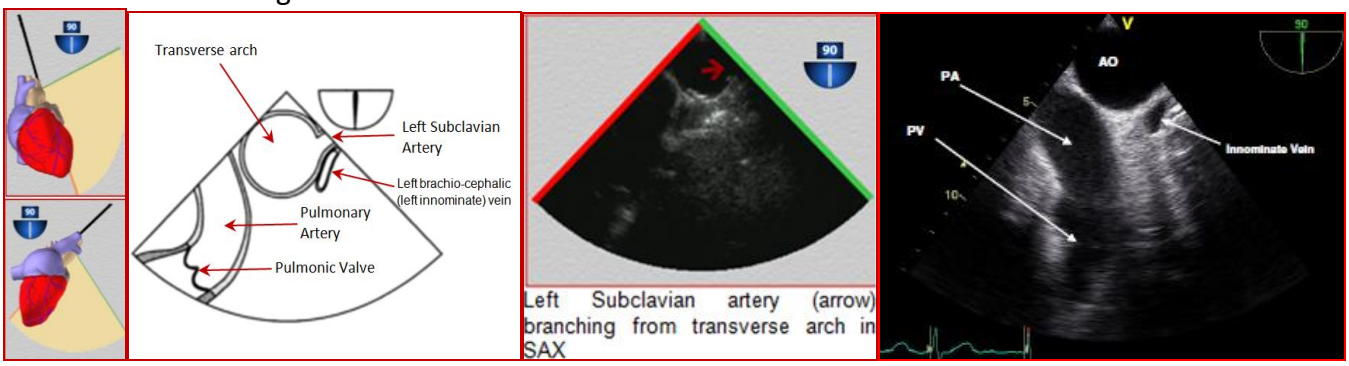

VI. Systematic Approach to Comprehensive TEE

- **ME 4c** (consider CS LAX, ME RV inflow-outflow, and ME mitral commissural) → **ME 2c** (optimize the LAA ± LUPV) → **ME Bicaval** (± RUPV) → **ME LAX** →
- **ME AV SAX** → **ME AV LAX** → **ME Asc Aorta SAX** → **ME Asc Aorta LAX** →
- **TG Mid SAX** (consider TG RV inflow) → **TG Basal SAX** (consider TG 2c, TG LAX, and Deep TG LAX) →
- **ME Desc Aorta SAX** → **ME Desc Aorta LAX** → **UE Aortic Arch LAX** → **UE Aortic Arch SAX**

1. ME 4-chamber 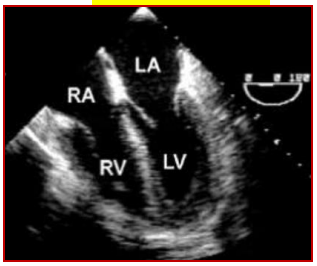 Angle **0°**, advance the probe **35cm** and **retroflex**	**2. ME 2-chamber** 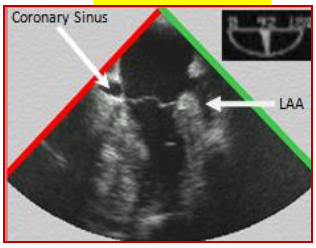 Rotate to **90°**	**3. ME Bicaval** 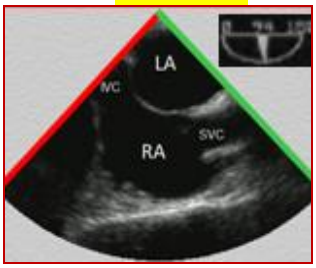 Turn the probe **rightward**	**4. ME LAX** 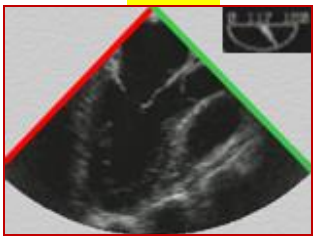 Rotate to **135°**
5. ME AV SAX 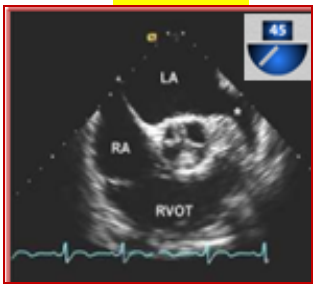 the probe tip is in the neutral position and rotate to 45°	**6. ME AV LAX** 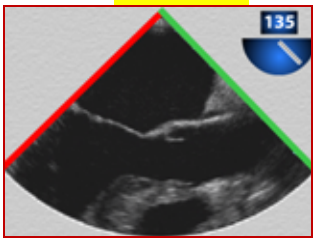 Rotate to 135°	**7. ME Asc Aortic SAX**  Withdraw (30 cm) until the RPA appears. Adjust the angle (0°) to optimize the circular aorta	**8. ME Asc aortic LAX** 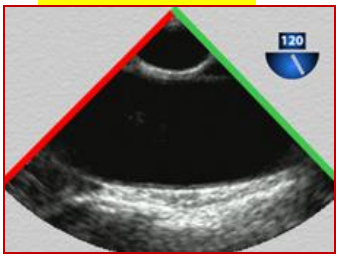 Rotate 90° form the SAX view
	9. TG Mid LV SAX 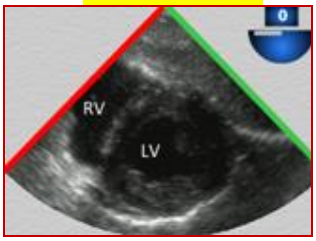 Angle 0°, advance the probe 45cm and anteflex	**10. TG Basal LV SAX** 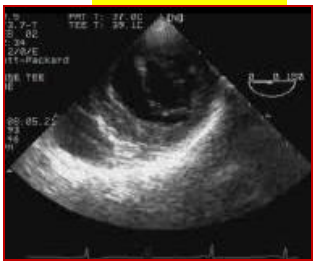 Slightly withdraw and further anteflex	
11. Desc aortic SAX 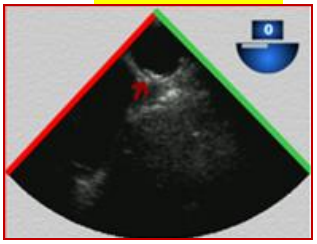 Angle 0^0, turn the probe 180^0 leftward	**12. Desc Aortic LAX** 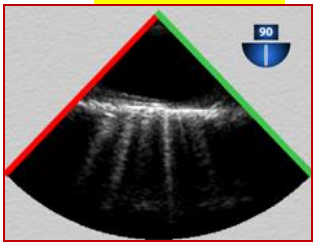 Rotate to 90°	**13. Aortic arch LAX**  angle 0°, withdraw (25 cm)	**14. Aortic arch SAX** 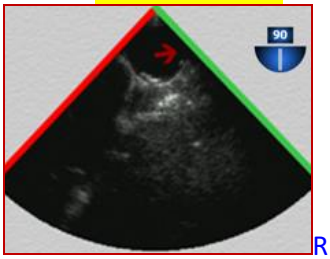 Rotate to 90°

Concise summary:

1) LV thrombi, MV vegetations, LAA thrombi, ASD

- ⇨ **35 cm, retroflex** → Angle **0-20** → ME- **LV-4c**
  → Angle **60** → **commissural**
- ⇨ Angle **90** → ME- **LV-2c** → withdraw and turn leftward → **LAA**
  → Turn probe rightward → ME **Bicaval (ASD)**
- ⇨ Angle **135** → ME **LV-LAX**

---

2) AV vegetations, Asc aorta aneurysm or dissection

- ⇨ Anteflex to **neutral position** → angle **45** → ME **AV-SAX**
  → Angle **135** → ME **AV-LAX**
- ⇨ Withdraw (30 cm); angle **0** → ME Asc (**Asc aorta-SAX**)
- ⇨ Angle **90** → ME Asc (**Asc aorta-LAX**)

---

3) LV thrombi

- ⇨ Advance (45 cm); anteflex → TG **Mid LV-SAX**
- ⇨ Slight withdrawal, further anteflexion → TG **basal LV-SAX**

---

4) Desc aorta and aortic arch aneurysm or dissection

- ⇨ Back to 4c; turn probe leftward 180 degree → **Desc aorta SAX** (advance and withdraw to interrogate the Desc thoracic aorta in SAX)
- ⇨ Angel 90 → **Desc aorta LAX** (advance and withdraw to interrogate the Desc thoracic aorta in LAX)
- ⇨ Back to Desc aorta SAX (angle 0); withdraw (25 cm) and turn rightward → UE **aortic arch LAX**
- ⇨ Angle 0 → UE **aortic arch SAX**

	SAX	**LAX**
LV	0 degree (TG)	135 degree (ME)
AV	45 degree	135 degree
Asc aorta, Desc aorta, aortic arch	0 degree	90 degree

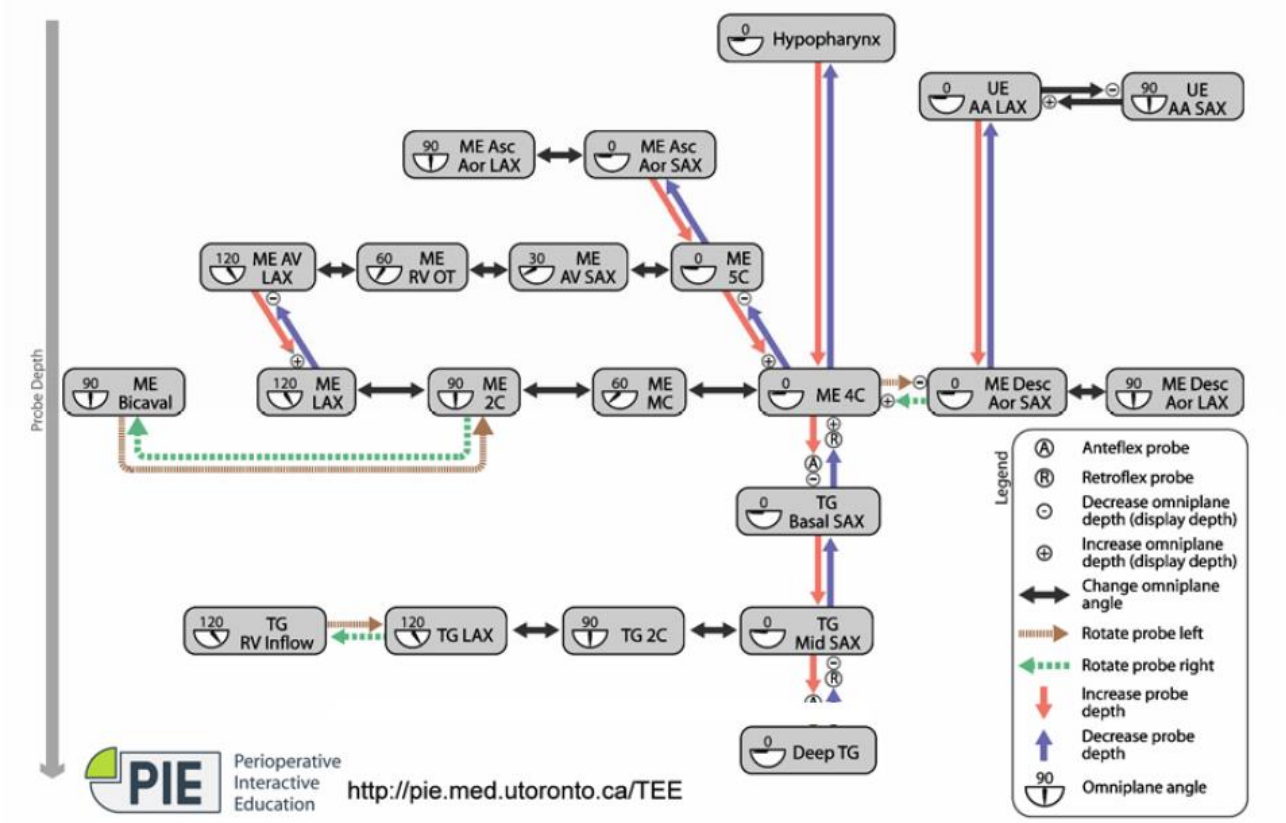
Basic TEE Views
TEE Template
Probe Depth
0 Hypopharynx
0 UE AA LAX
90 UE AA SAX
90 ME Asc Aor LAX
0 ME Asc Aor SAX
120 ME AV LAX
60 ME RV OT
30 ME AV SAX
0 ME 5C
90 ME Bicaval
120 ME LAX
90 ME 2C
60 ME MC
0 ME 4C
0 ME Desc Aor SAX
90 ME Desc Aor LAX
0 TG Basal SAX
120 TG RV Inflow
120 TG LAX
90 TG 2C
0 TG Mid SAX
0 Deep TG
Legend
Anteflex probe
Retroflex probe
Decrease omniplane depth (display depth)
Increase omniplane depth (display depth)
Change omniplane angle
Rotate probe left
Rotate probe right
Increase probe depth
Decrease probe depth
Omniplane angle
PIE
Perioperative Interactive Education
http://pie.med.utoronto.ca/TEE